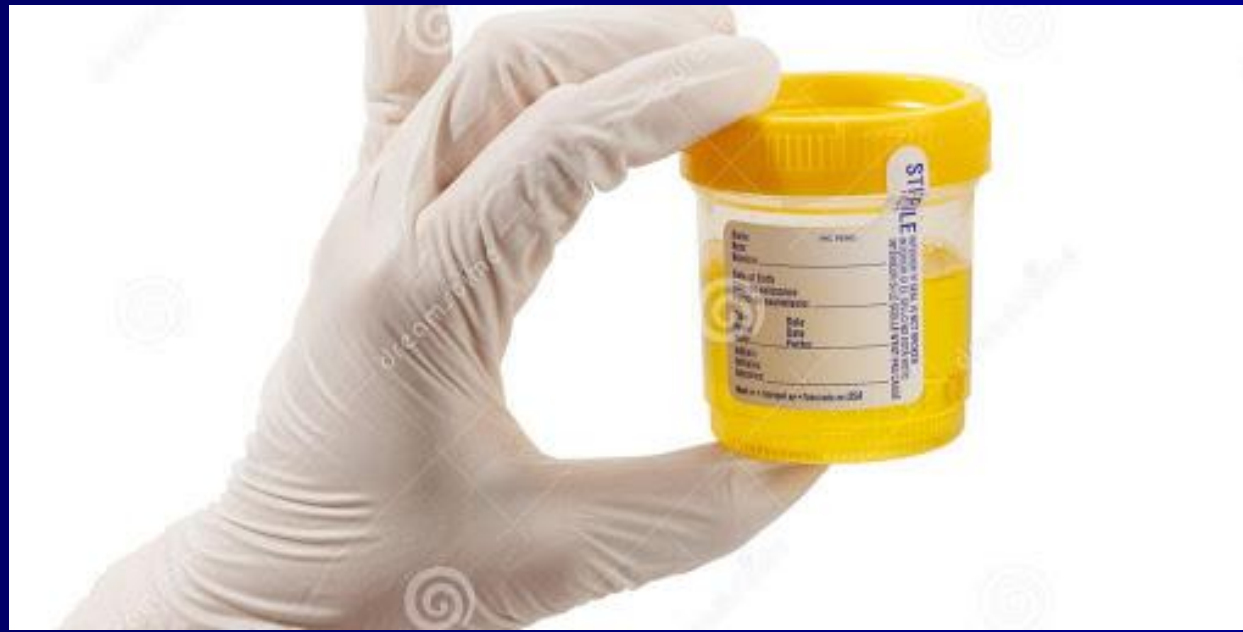

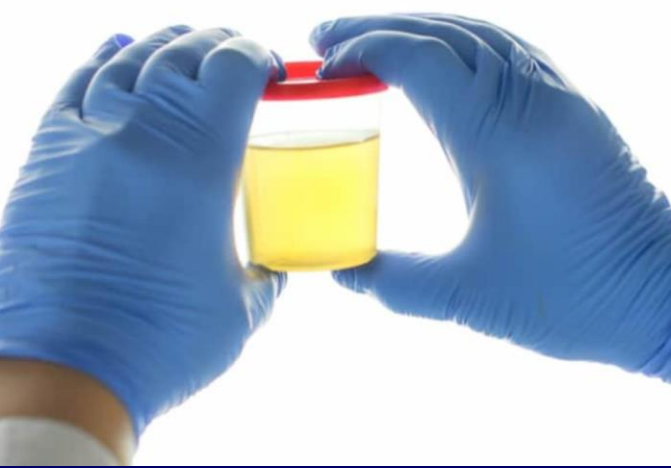Urinalysis

- **Dr. Hossein Javid (MSc, PhD)**
 - **Ph.D in Medical Biochemistry**
 - Department of Clinical Biochemistry, Faculty of Medicine, Mashhad University of Medical Sciences, Mashhad, Iran.
 - **M.Sc. in Medical Biochemistry**
 - Department of Clinical Biochemistry, Faculty of Medicine, Mashhad University of Medical Sciences, Mashhad, Iran.
 - **B.Sc. in Medical Lab Sciences**
 - Golestan University of Medical Sciences, Gorgan, Iran

Specimen Collection

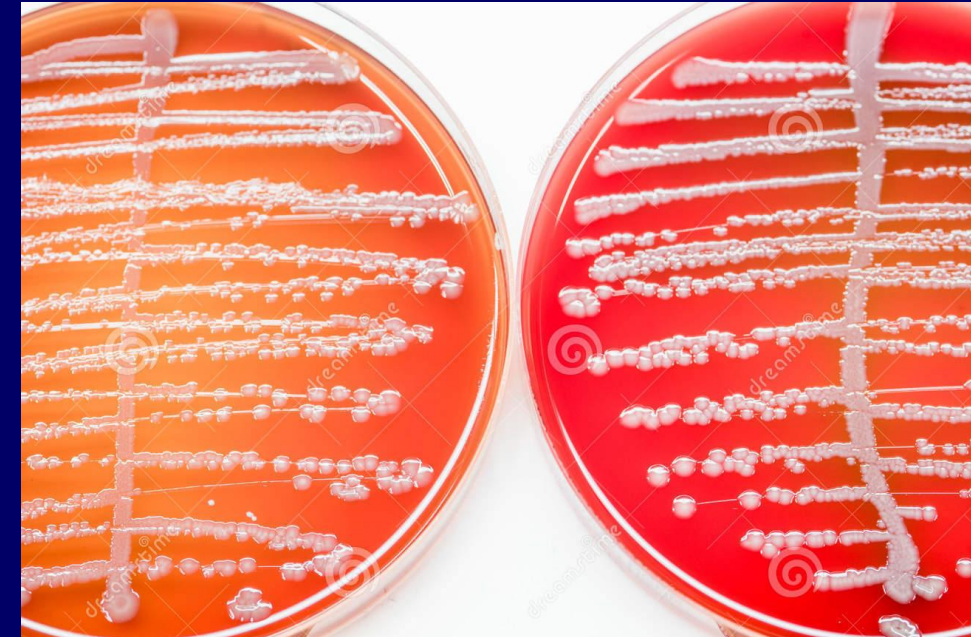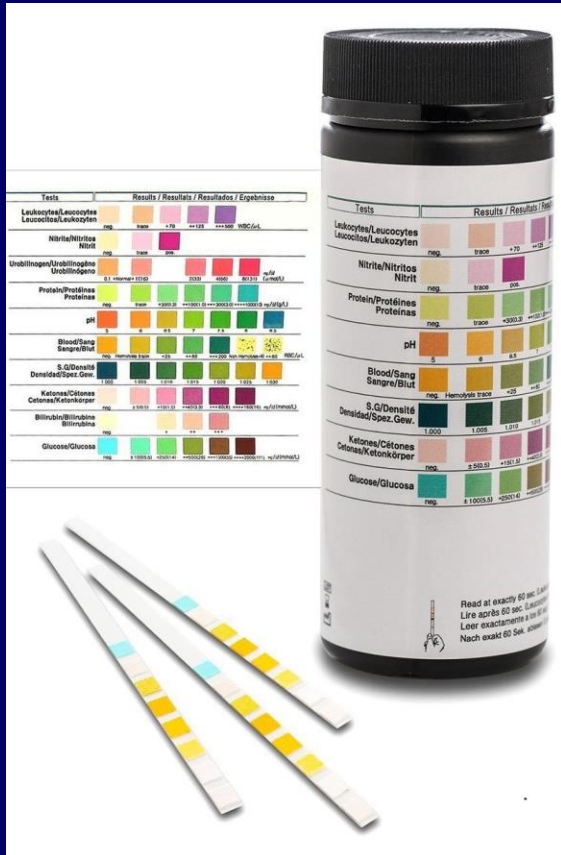
- **First morning voiding (most concentrated)**
- **Type of specimen (e.g. “clean catch”)**
- **Analyzed within 2 hours of collection**





Types of Analysis

- Macroscopic Examination
- Chemical Analysis (Urine Dipstick)
- Microscopic Examination
- Culture



Macroscopic Examination

Odor:

- **Foul, offensive:** Old specimen, pus or inflammation
- **Sweet:** Glucose
- **Fruity:** Ketones
- **Maple syrup-like:** Maple Syrup Urine Disease

Color:

- **Colorless** Diluted urine
- **Deep Yellow** Concentrated Urine
- **Yellow-Green** Bilirubin / Biliverdin
- **Red** Blood / Hemoglobin
- **Brownish-red** Acidified Blood (Acute GN)
- **Brownish-black** Homogentisic acid

Macroscopic Examination

Turbidity:

- Typically cells or crystals.
- Cellular elements and bacteria will clear by centrifugation.
- **Microscopic examination** will determine which is present.

Chemical Analysis

Urine Dipstick

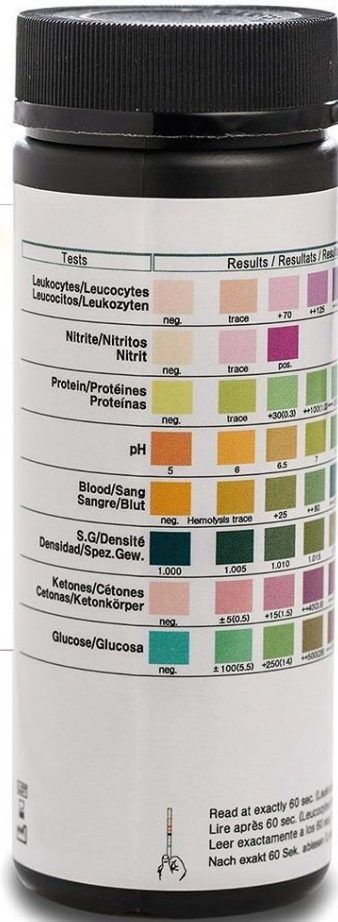
One Step®

Reagent Strips For Urinalysis
Bandelettes Reactives Pour L'analyse Urinaire
Reagenz Streifen Für Urinanalyse
Tiras Reactivas Para Analisis De Orina

CE 0120 IVD

2°C 30°C

Tests	Results / Resultats / Resultados / Ergebnisse
Leukocytes/Leucocytes Leucocitos/Leukozyten	neg. trace +70 **125 ***500 WBC/µL
Nitrite/Nitritos Nitrit	neg. trace pos.
Urobilinogen/Urobilinogéno Urobilinogeno	0.1 +Normal+ 1(1.6) 2(3.3) 4(6.6) 8(13.2) µg/dl (µmol/L)
Protein/Protéines Proteínas	neg. +200.33 **1001.01 ***2003.01 ****10003.01 µg/dl (µg/L)
pH	5 6 6.5 7 7.5 8 8.5
Blood/Sang Sangre/Blut	neg. Hemolyzed trace +25 **50 ***200 Non Hemolyzed +**50 RBC/µL
S.G./Densité Densidad/Spz.Gew.	1.000 1.005 1.010 1.015 1.020 1.025 1.030
Ketones/Cétones Cetones/Ketonkörper	neg. ± 150.53 ±151.53 ±453.33 ±605.33 ±1515.33 ±1516.33 µg/dl (mmol/L)
Bilirubin/Bilirubine Bilirubina	neg. *
Glucose/Glucosa	neg. ± 10005.53 ±2501.41 ±5002.83 ±10005.66 ±20011.33 µg/dl (mmol/L)

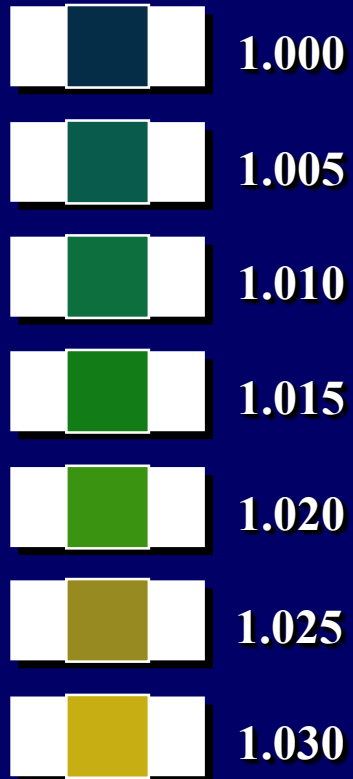


- Glucose*
- Bilirubin*
- Ketones*
- Specific Gravity*
- Blood*
- pH*
- Protein*
- Urobilinogen*
- Nitrite*
- Leukocyte*

Read at exactly 60 sec. (Lambert)
Lire après 60 sec. (Lambert)
Leer exaktamente a los 60 seg.
Nach exakt 60 Sek. ablesen

The Urine Dipstick:

Specific Gravity




✓ شاخص غلظت مواد محلول در ادرار است.
✓ برای سنجش قدرت تغلیظ و رقیق کردن کلیه ها به منظور حفظ هموستاز مایعات بدن و الکترولیت ها به کار می رود.
✓ اوره (۲۰ درصد)، سدیم کلراید (۲۵ درصد)، سولفات و فسفات بیشترین سهم را در وزن مخصوص ادرار طبیعی دارند.

پلی اتیل مالئیک اسید احیا می شود. و H^+ آن با معرف (Bromthymol Blue)

The Urine Dipstick:

PH



Chemical Principle

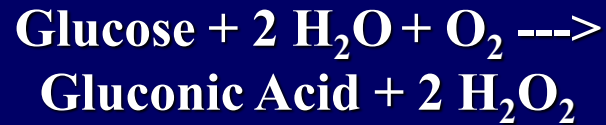
H⁺ interacts with:
Methyl Red (at **high** concentration; **low pH**)
and
Bromthymol Blue (at **low** concentration; **high pH**), to form a colored complexes
(dual indicator system)

Read up to 2 minutes
R.R.: 4.5-8.0

The Urine Dipstick

Chemical Principle

Glucose Oxidase



Horseradish Peroxidase



Read at 30 seconds

RR: Negative

Glucose



Negative



Trace (100 mg/dL)



+ (250 mg/dL)



++ (500 mg/dL)



+++ (1000 mg/dL)



++++ (2000+ mg/dL)

Uses and Limitations of Urine Glucose Detection

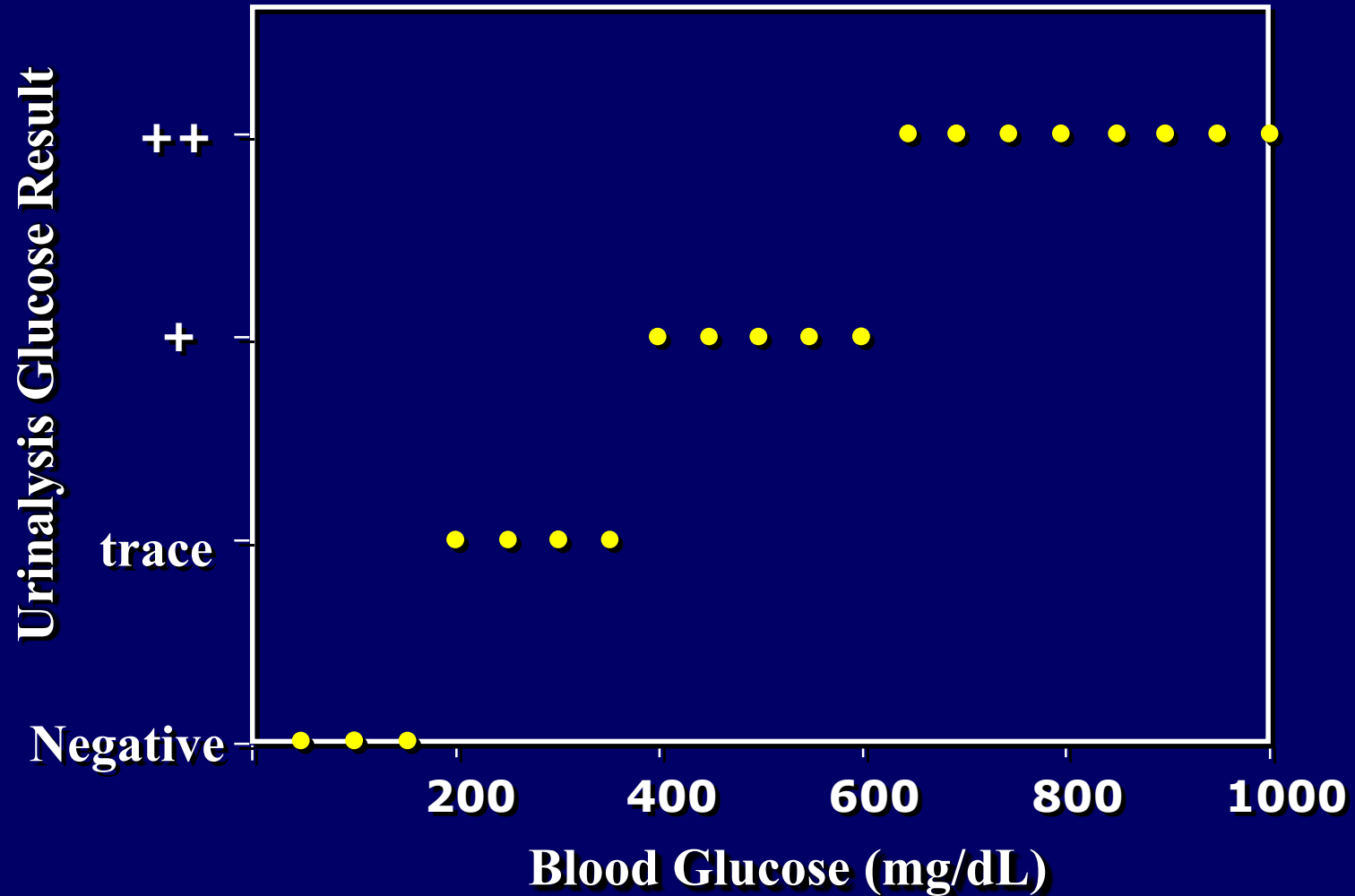
Significance

- **Diabetes mellitus.**
- **Renal glycosuria.**

Limitations

- **Interference: reducing agents**
- **Only measures glucose and not other sugars.**
- **Renal threshold must be passed in order for glucose to spill into the urine.**

Urine versus Blood Glucose



The Urine Dipstick:

Ketones

Chemical Principle

Acetoacetic Acid + Nitroprusside -----> Colored Complex

Read at 40 seconds

RR: Negative



Negative



Trace (5 mg/dL)



+ (15 mg/dL)



++ (40 mg/dL)



+++ (80 mg/dL)



++++ (160+ mg/dL)

Uses and Limitations of Urine Ketone Detection

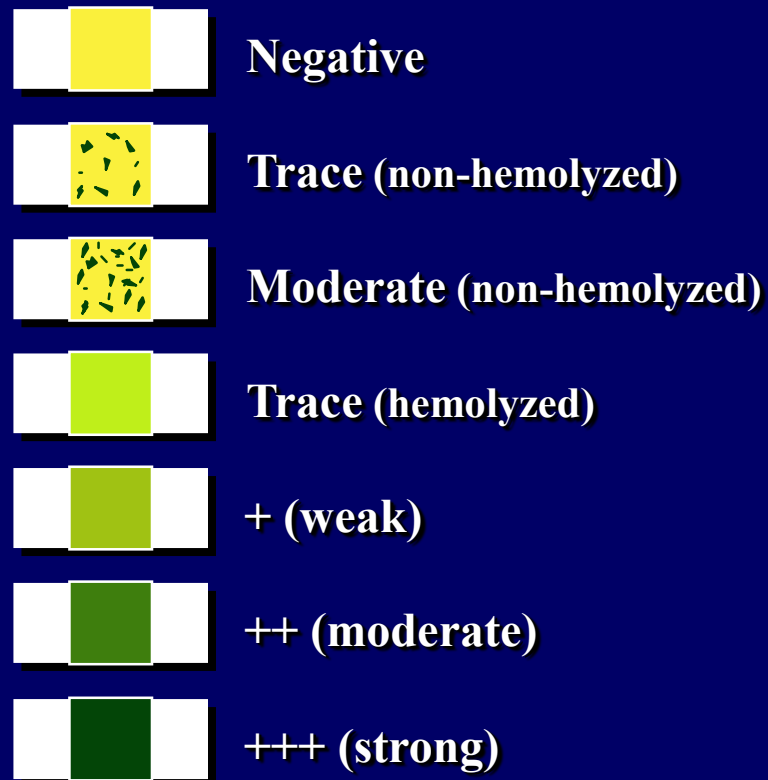
Significance

- Diabetic ketoacidosis
- Prolonged fasting

Limitations

- Interference: expired reagents (degradation with exposure to moisture in air)
- Only measures acetoacetate not other ketone bodies.

The Urine Dipstick:



Blood

Chemical Principle

Lysing agent to lyse red blood cells

Diisopropylbenzene dihydroperoxide +
Tetramethylbenzidine

-----*Heme*-----> Colored Complex

Read at 60 seconds

RR: Negative

Analytic Sensitivity: 8 RBCs

Uses and Limitations of Urine Blood Detection

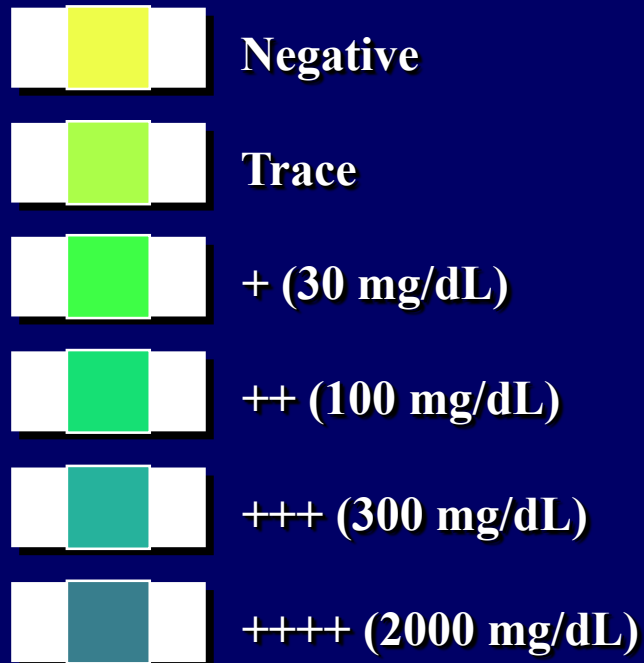
Significance

- Hematuria (nephritis, trauma, etc)
- Hemoglobinuria (hemolysis, etc)
- Myoglobinuria (rhabdomyolysis, etc)

Limitations

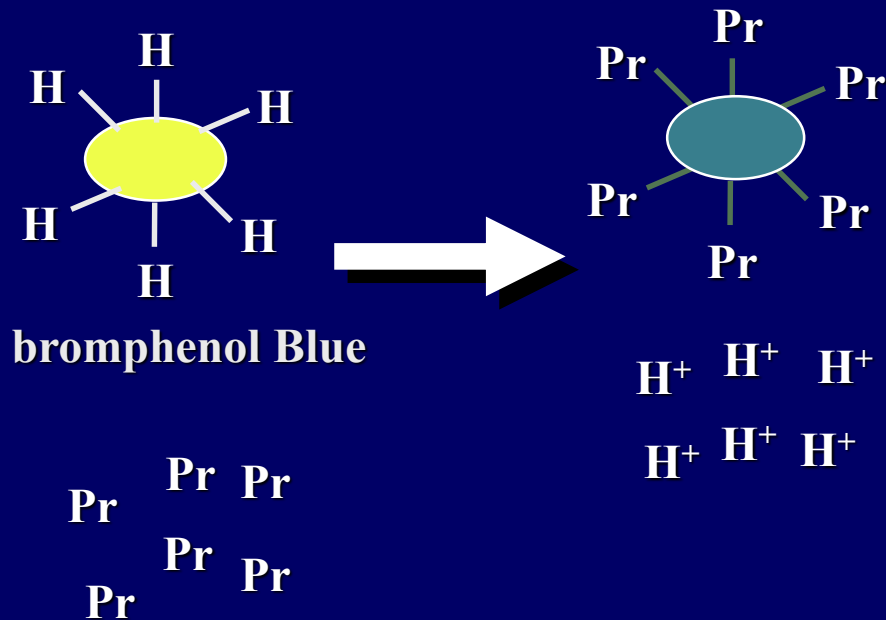
- Interference: reducing agents, microbial peroxidases
- Cannot distinguish between the above disease processes

The Urine Dipstick:




Protein

Chemical Principle



Read at 60 seconds
RR: Negative

Sulphosalicylic Acid Test



Negative

Trace

1+

2+

3+



Urine Protein

Causes of Proteinuria

Functional

- Severe muscular exertion
- Pregnancy
- Orthostatic proteinuria

Renal

- Glomerulonephritis
- Nephrotic syndrome
- Renal tumor or infection

Pre-Renal

- Fever
- Renal hypoxia
- Hypertension

Post-Renal

- Urinary tract obstruction
- prostatitis

The Urine Dipstick:

Nitrite

Chemical Principle

Nitrite + p-arsenic acid $\xrightarrow{\text{Acidic}}$ Diazo compound

Diazo compound + Tetrahydrobenzoquinolinol
 $\xrightarrow{\hspace{1cm}}$ Colored Complex

Read at 60 seconds

RR: Negative



Negative



Positive

Gram negative

Uses and Limitations of Nitrite Detection


Significance

- Gram negative bacteriuria

Limitations

- Interference: bacterial overgrowth
- Only able to detect bacteria that reduce nitrate to nitrite

The Urine Dipstick:



Leukocyte Esterase

Chemical Principle

Derivatized pyrrole amino acid ester

Esterases → 3-hydroxy-5-phenyl pyrrole

3-hydroxy-5-phenyl pyrrole + diazo salt
-----> Colored Complex

Read at 2 minutes

RR: Negative

Analytic Sensitivity: 3-5 WBCs

Uses and Limitations of Leukocyte Esterase Detection

Significance

- Pyuria
- Acute inflammation
- Renal inflammation

Limitations

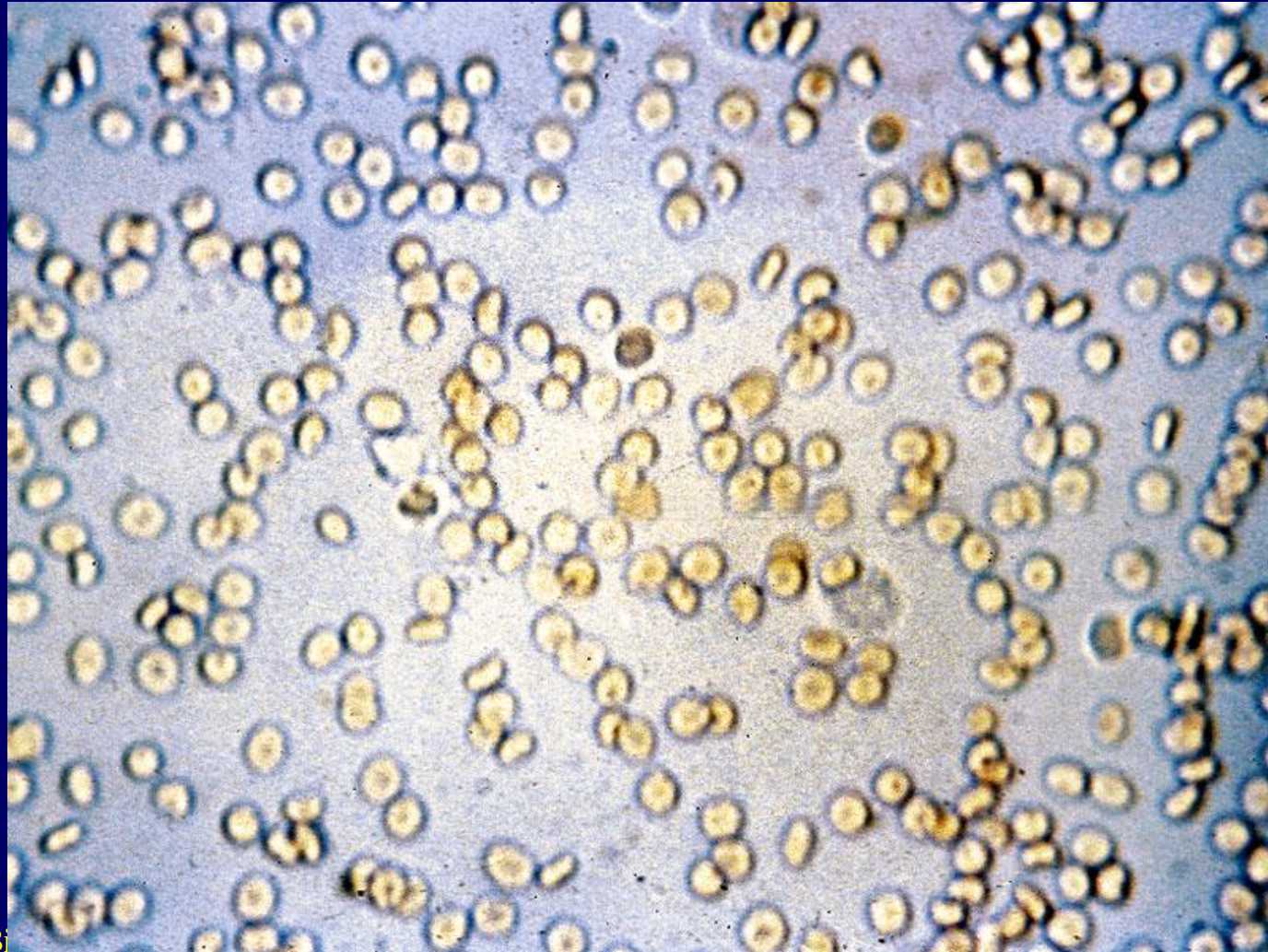
- Interference: oxidizing agents, menstrual contamination

Microscopic Examination



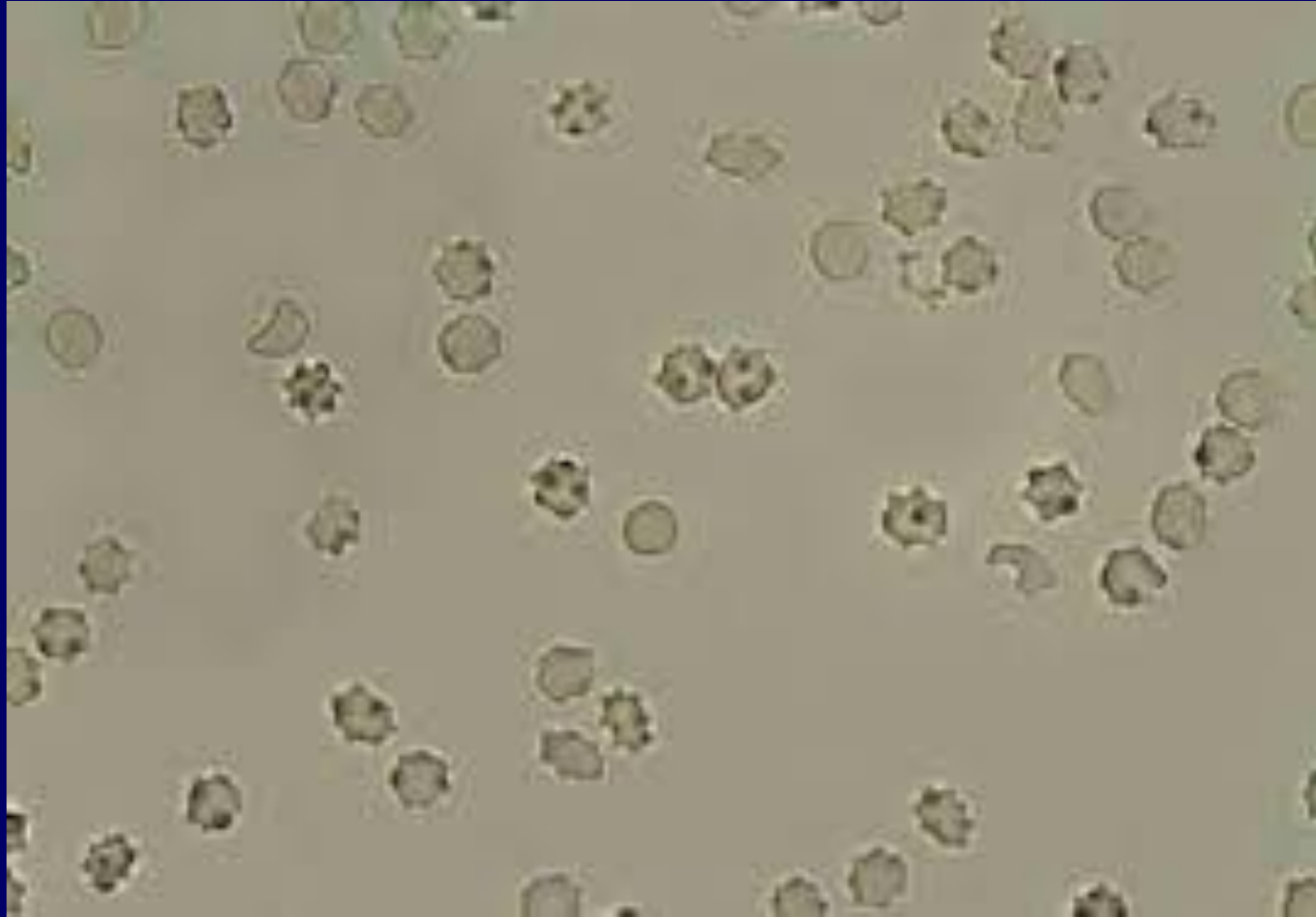
Microscopic Examination

RBCs



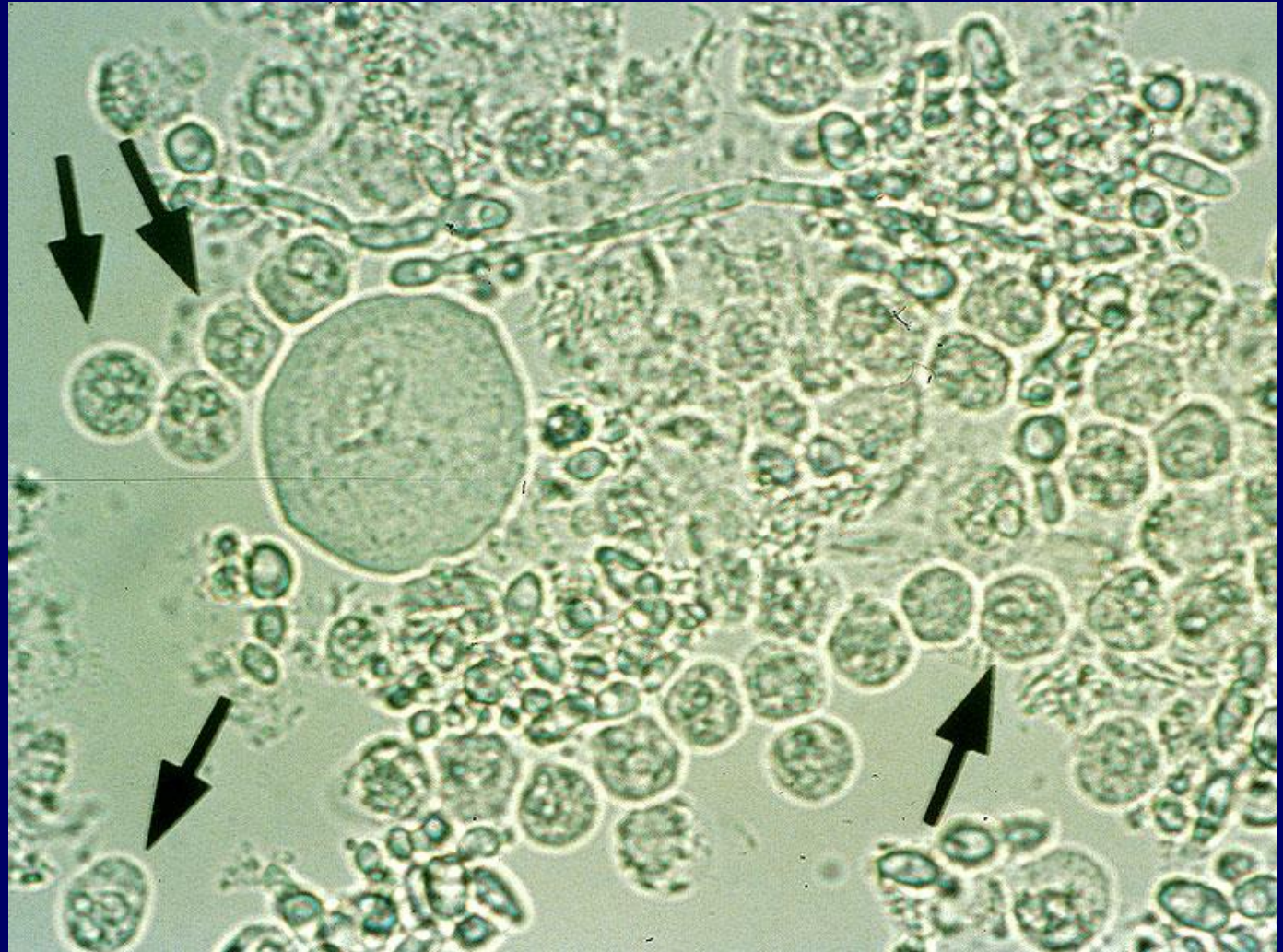Microscopic Examination

RBCs



Microscopic Examination

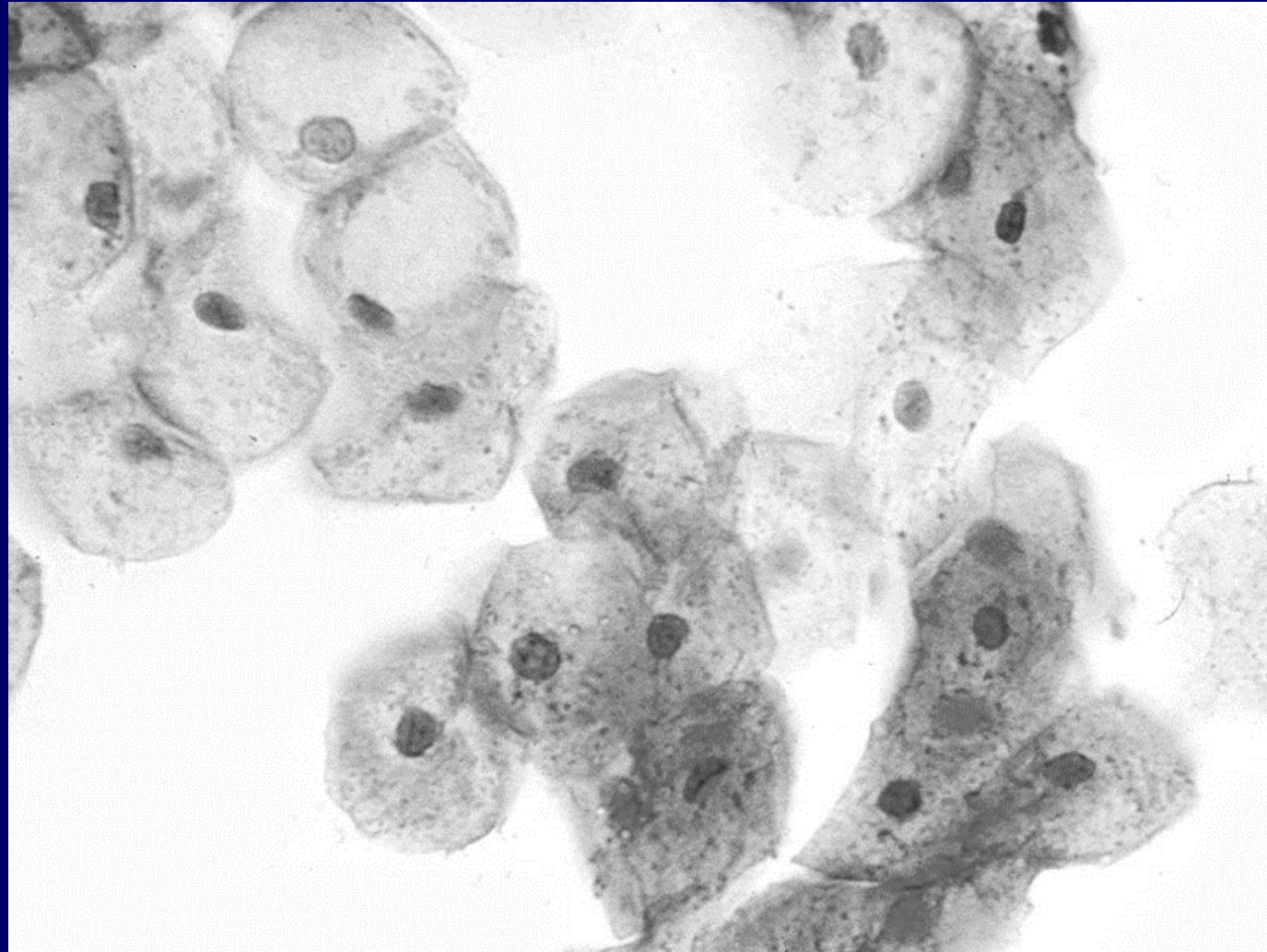
WBCs



- التهاب مثانه: این یک نوع عفونت ادراری است که بر مثانه تاثیر می گذارد.
- اورتریت (عفونت مجاری ادراری): این یک عفونت ادراری است که بر مجاری ادرار تاثیر می گذارد.
- عفونت کلیه: این یک **UTI** است که بر کلیه ها تاثیر می گذارد.

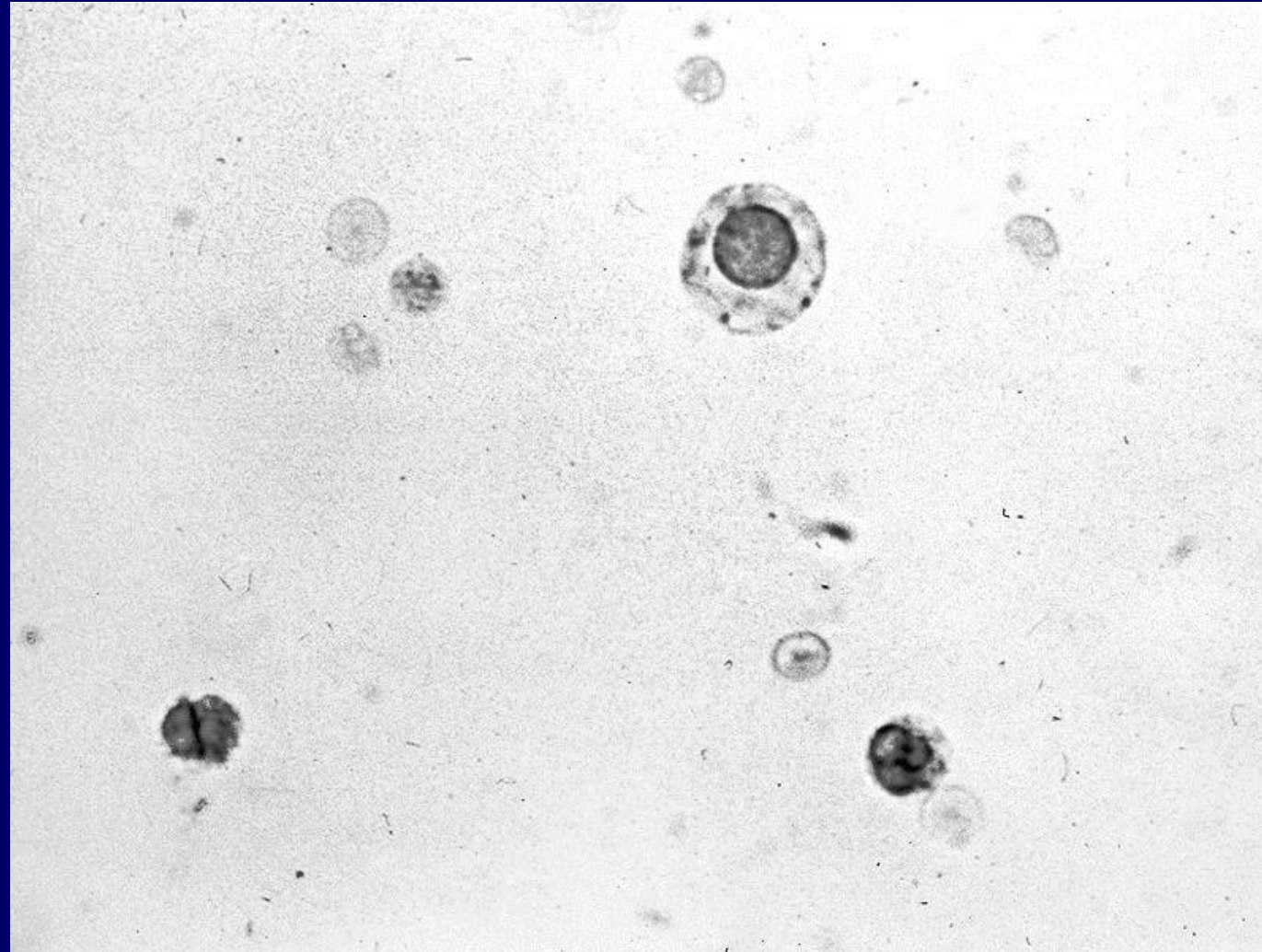
Microscopic Examination

Squamous Cells



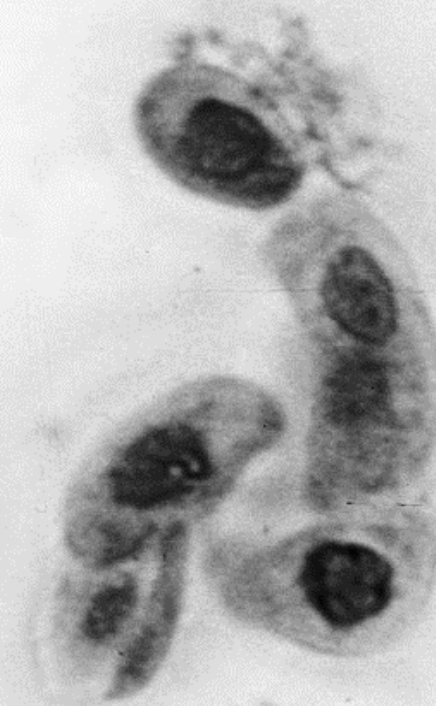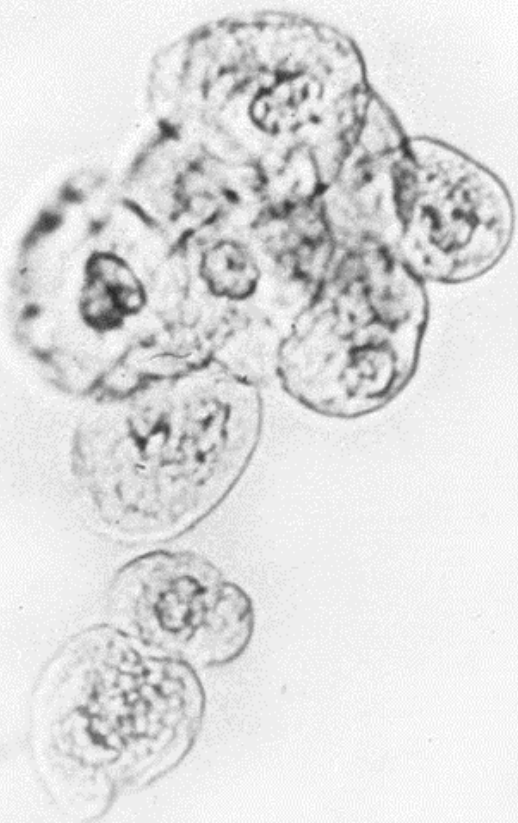
Microscopic Examination

Renal-Tubular Epithelial Cells



Microscopic Examination

Transitional Cells



Microscopic Examination

Bacteria & Yeasts

Bacteria

- Bacteriuria

More than 10 per HPF

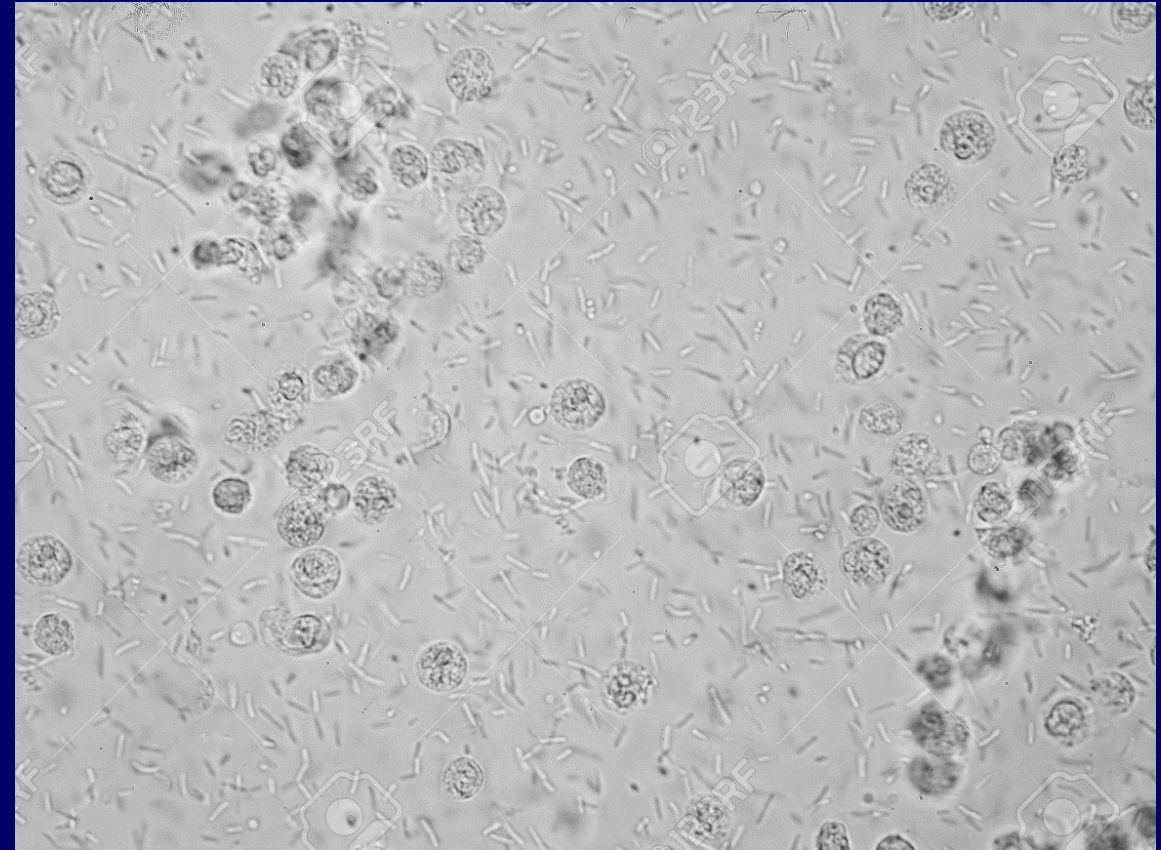
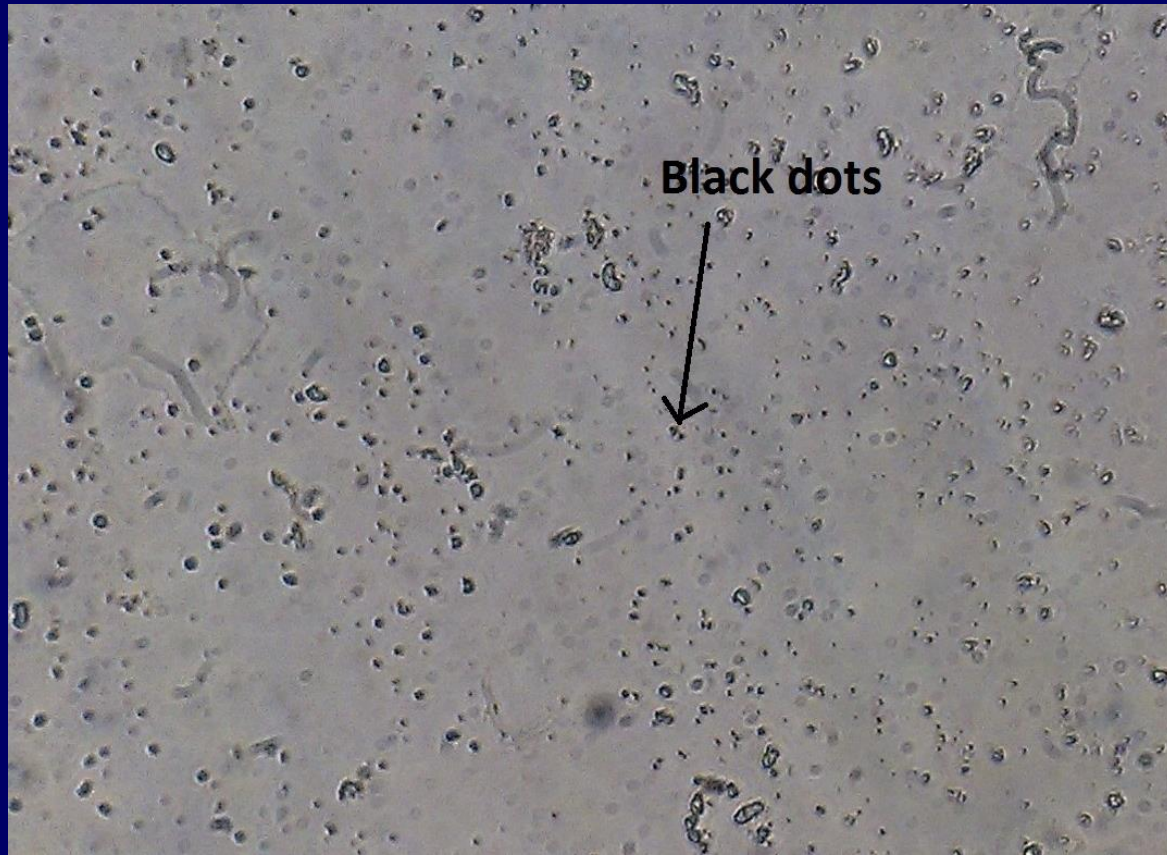
Yeasts

- Candidiasis

Most likely a contaminant

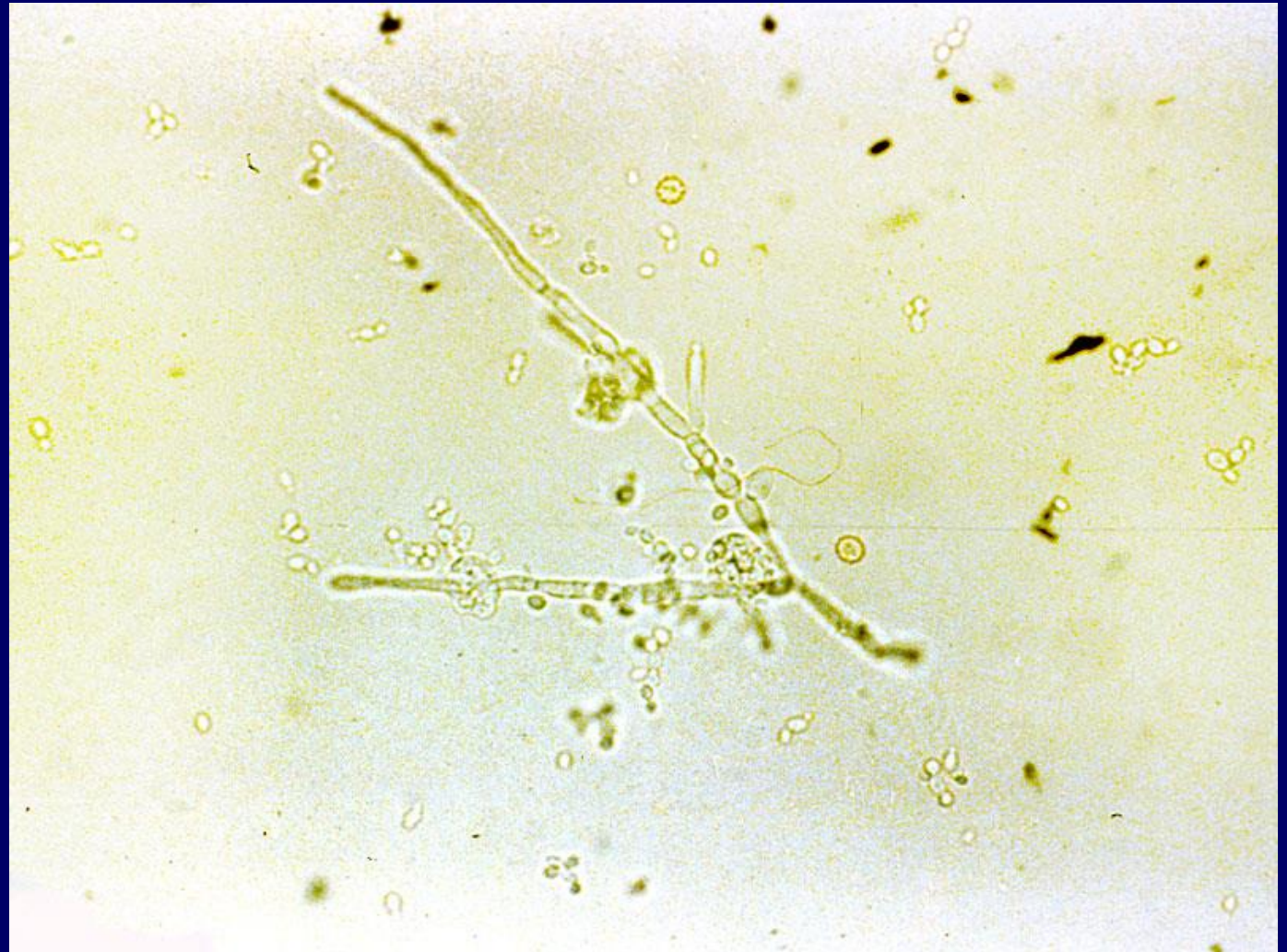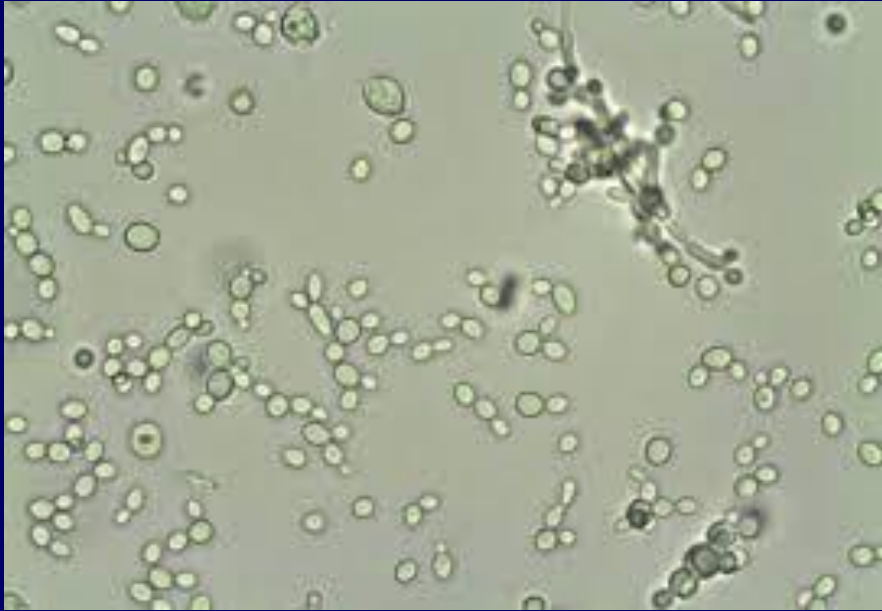Microscopic Examination

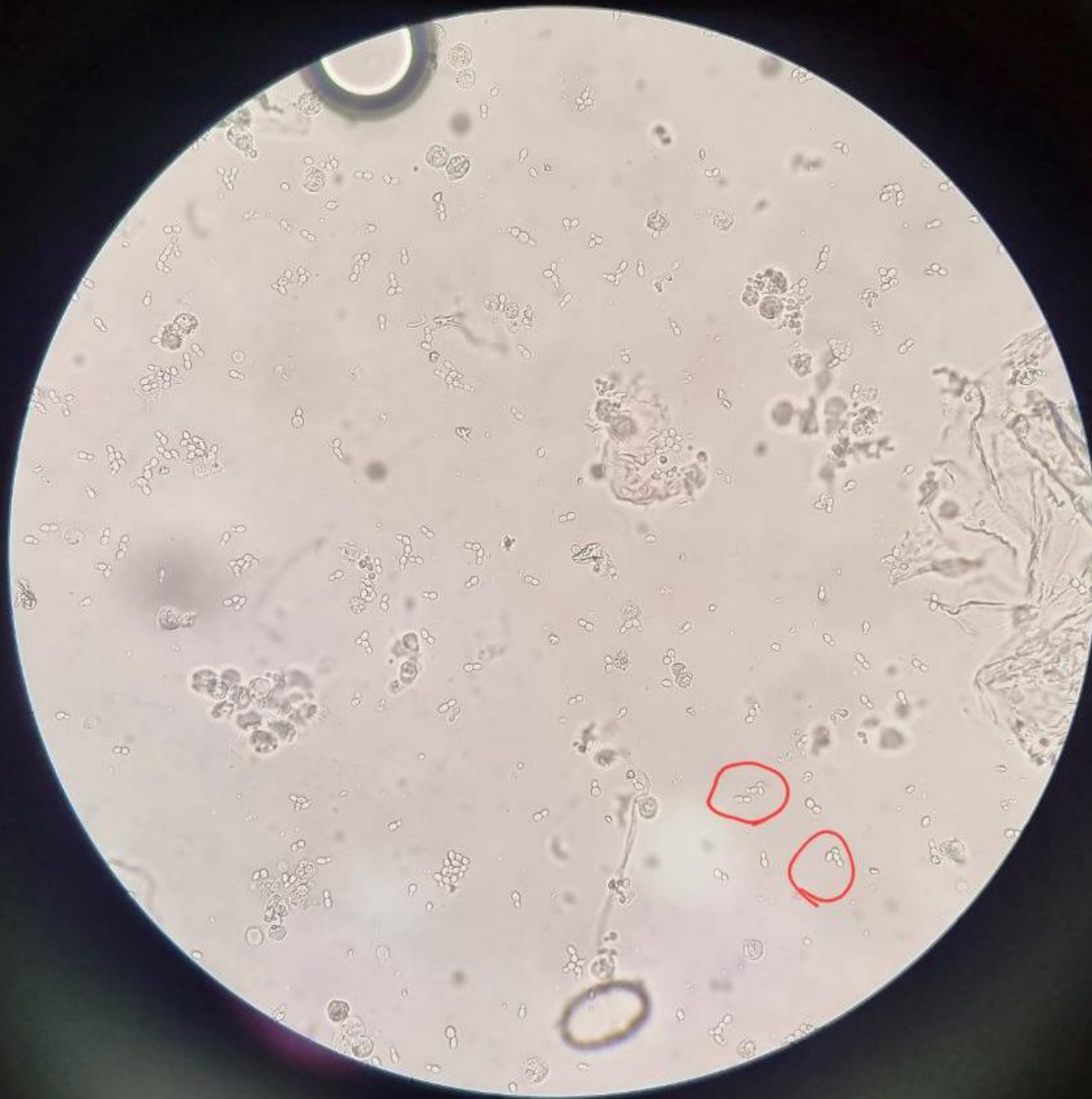
Bacteria



Microscopic Examination

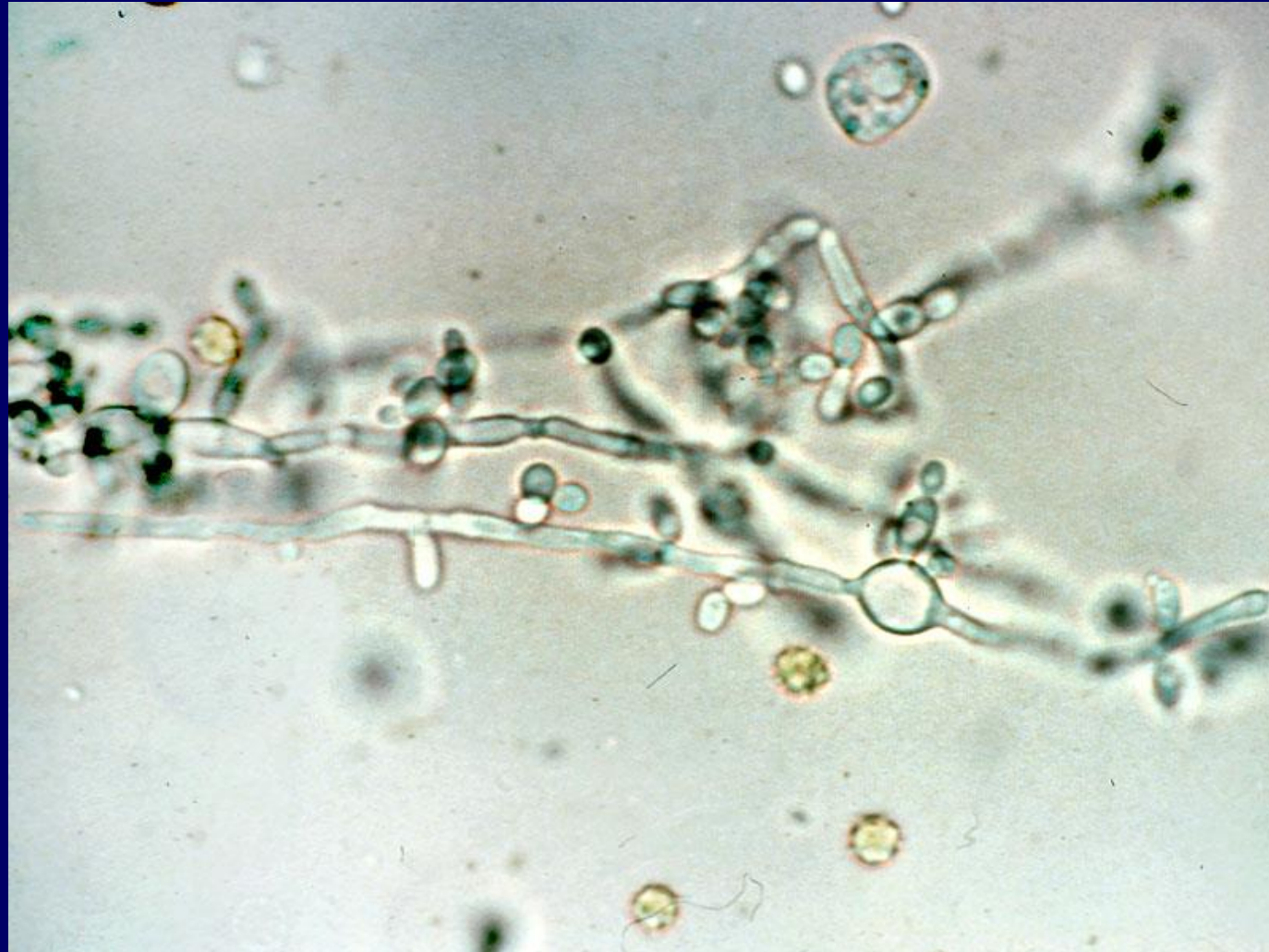Yeasts

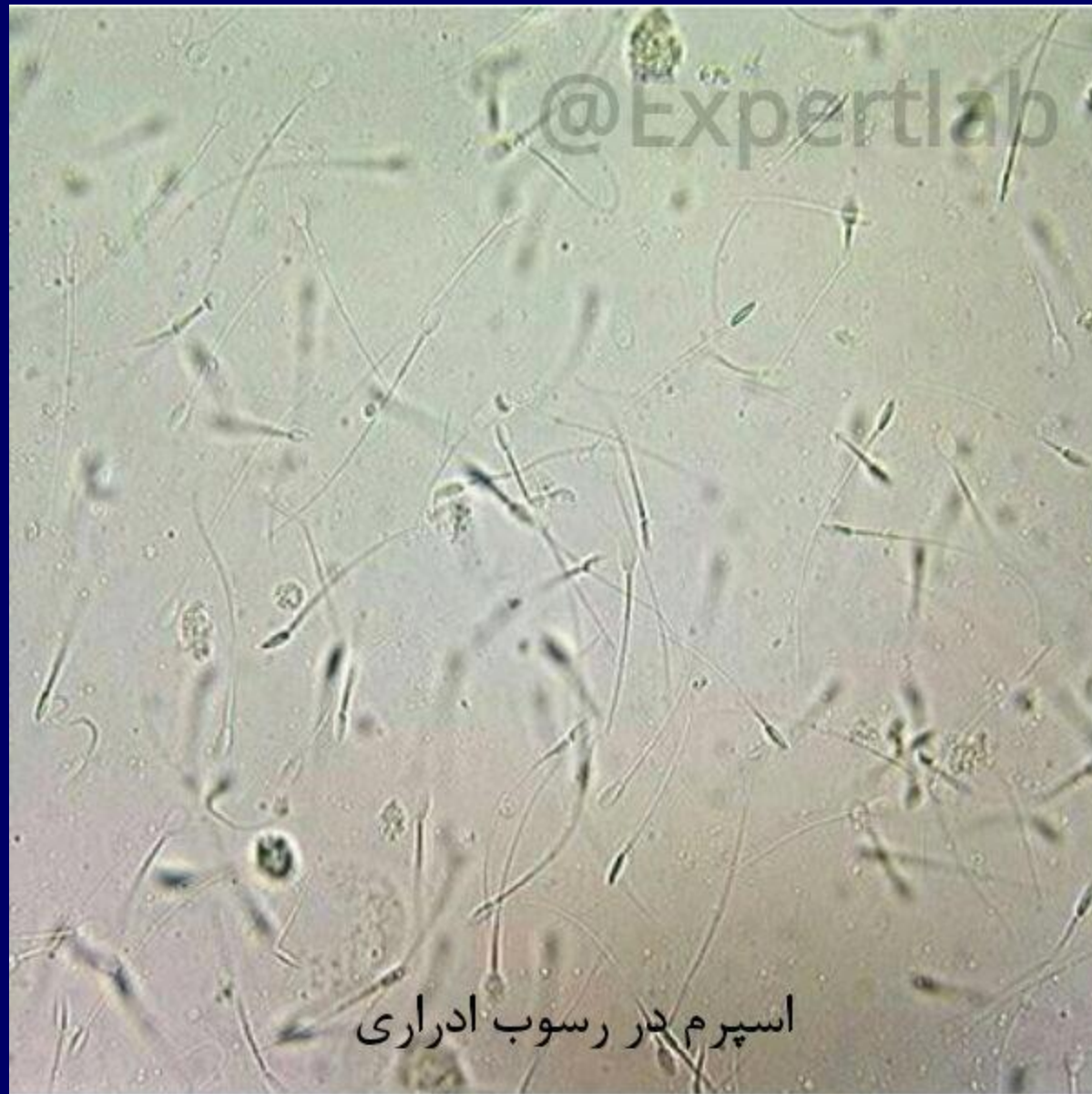



Microscopic Examination

Yeasts





اسپرم در رسوب ادراری

Microscopic Examination

Casts

Erythrocyte Casts:

Glomerular diseases

Leukocyte Casts:

Pyuria, glomerular disease

Degenerating Casts:

- Granular casts

Nonspecific (Tamm-Horsfall protein)

- Hyaline casts

Nonspecific (Tamm-Horsfall protein)

- Waxy casts

Nonspecific

- Fatty casts

Nephrotic syndrome

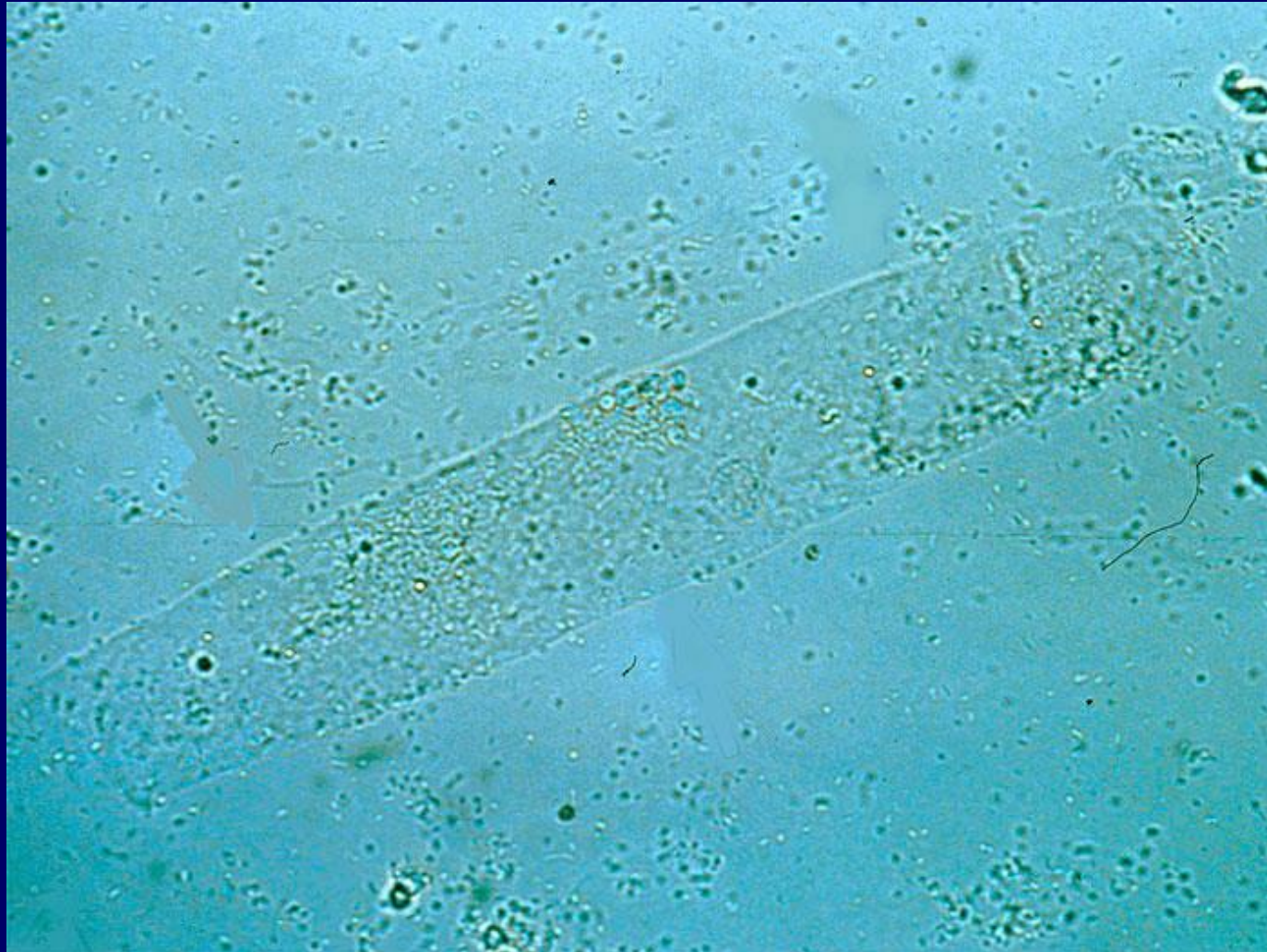
(oval fat body casts)

فقط در توبول دیستال و مجاری جمع کننده

Tamm-Horsfall protein

Microscopic Examination

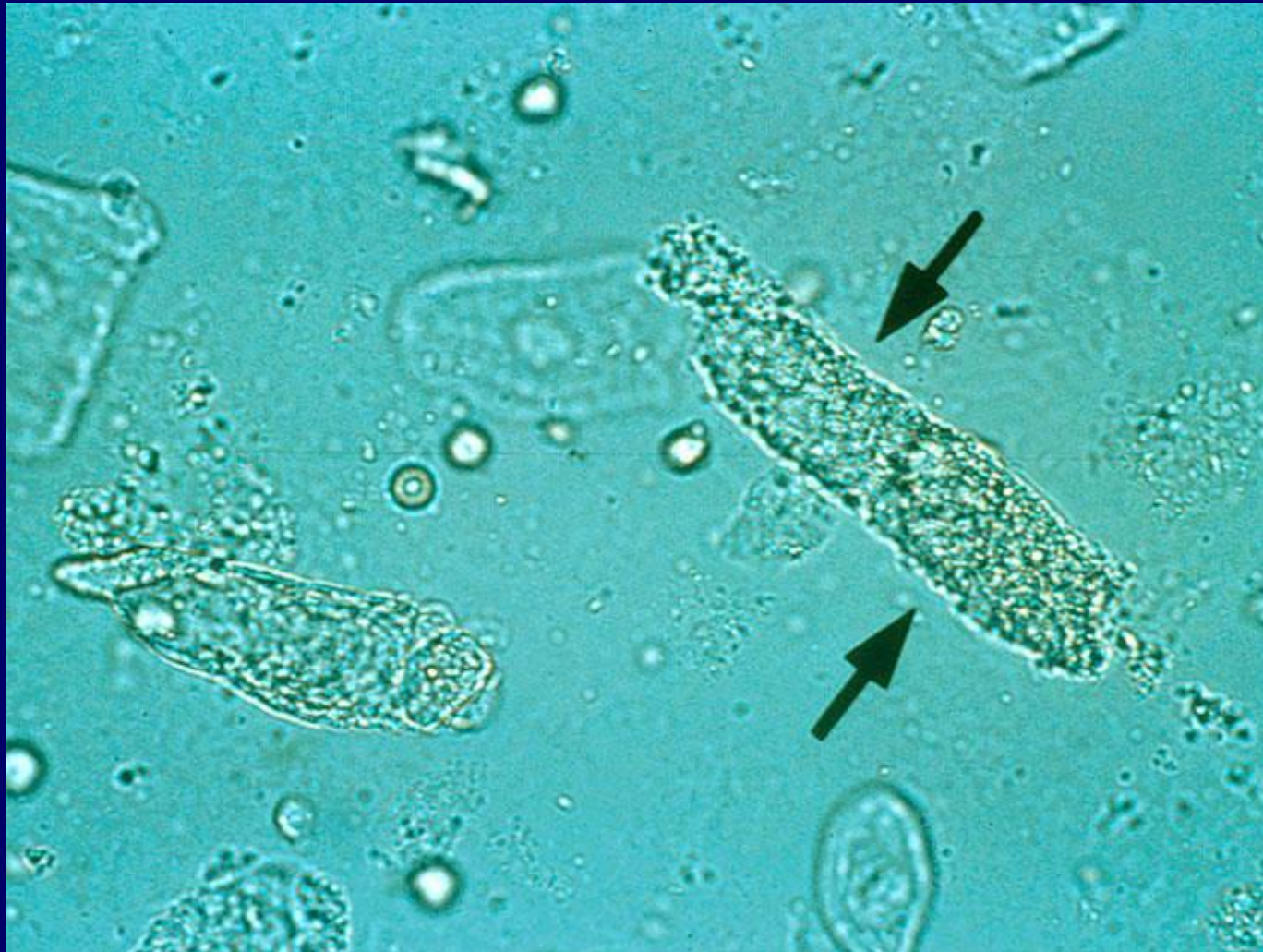Hyaline Cast



فقط از ماده زمینه ای

Microscopic Examination

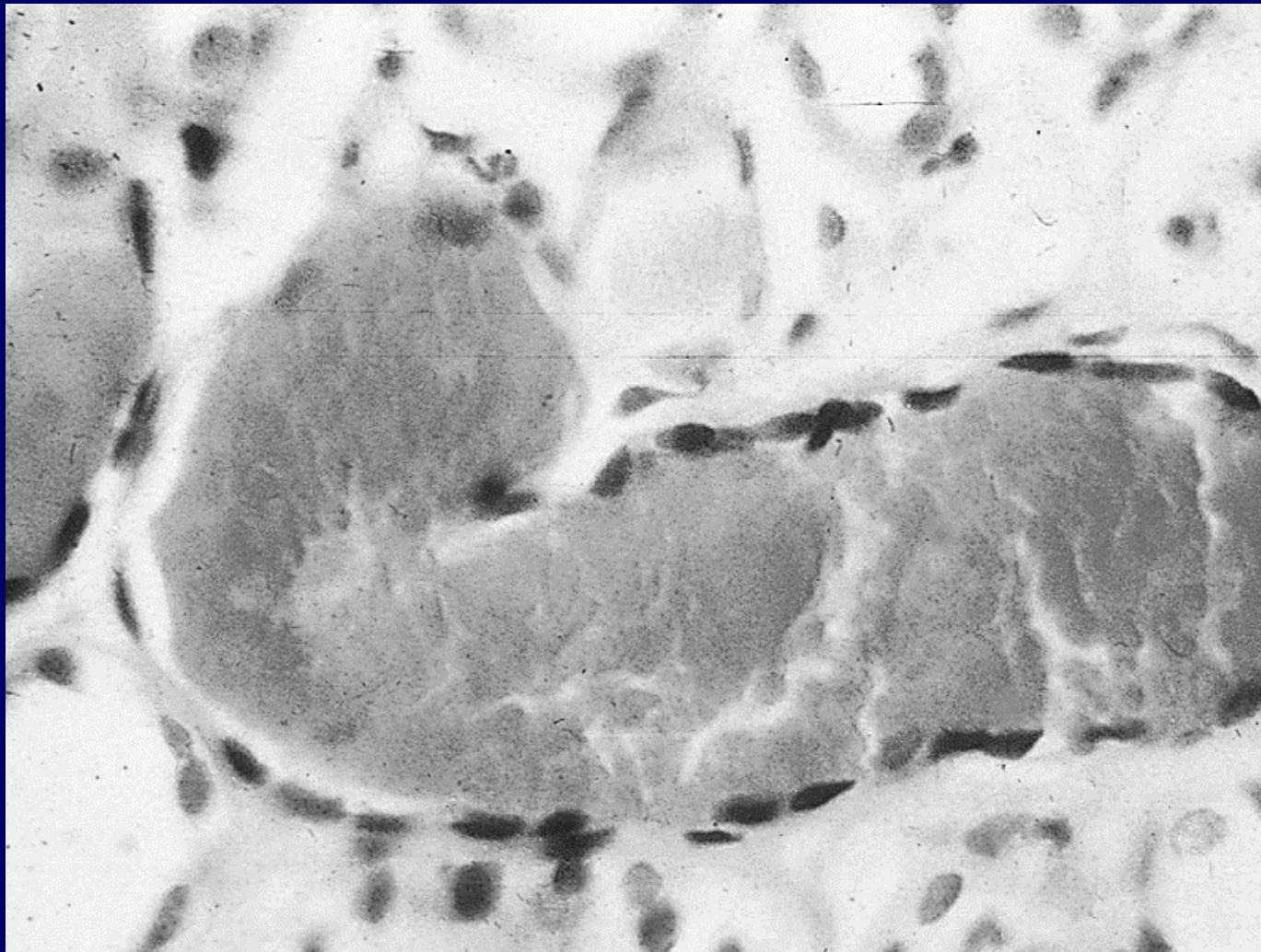
Granular Cast



در نتیجه دژنره شدن گلبولهای سفید یا سلولهای اپیتلیال
بیماری های مزمن کلیوی و در عفونتهای ادراری

Microscopic Examination

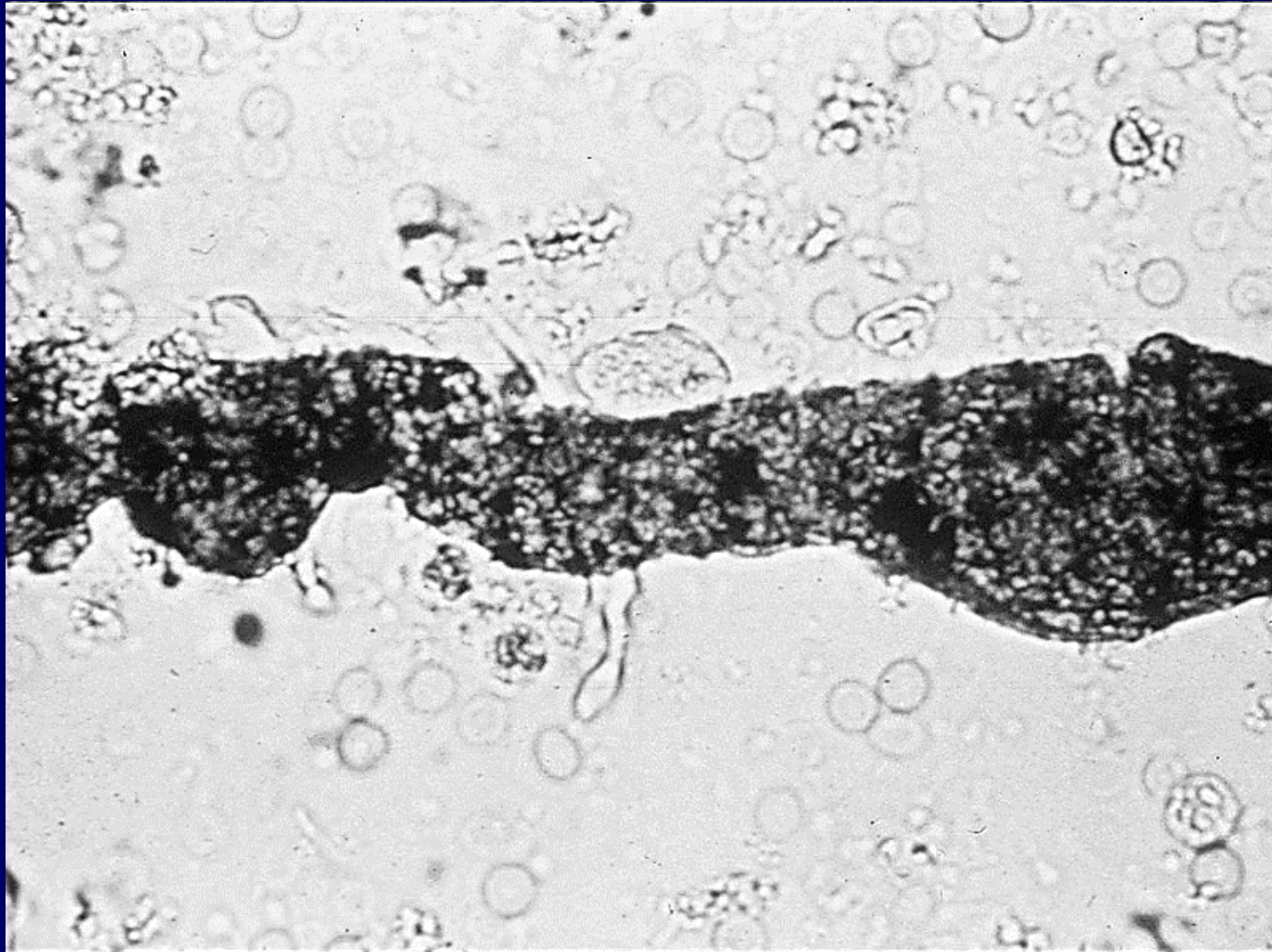RBCs Cast - Histology



اسیب غشا پایه گلومرولی است و مهمترین سیلندر در ادرار
گلومرونفریت حاد - نفریت لوپوسی و سندرم گود پاسچر

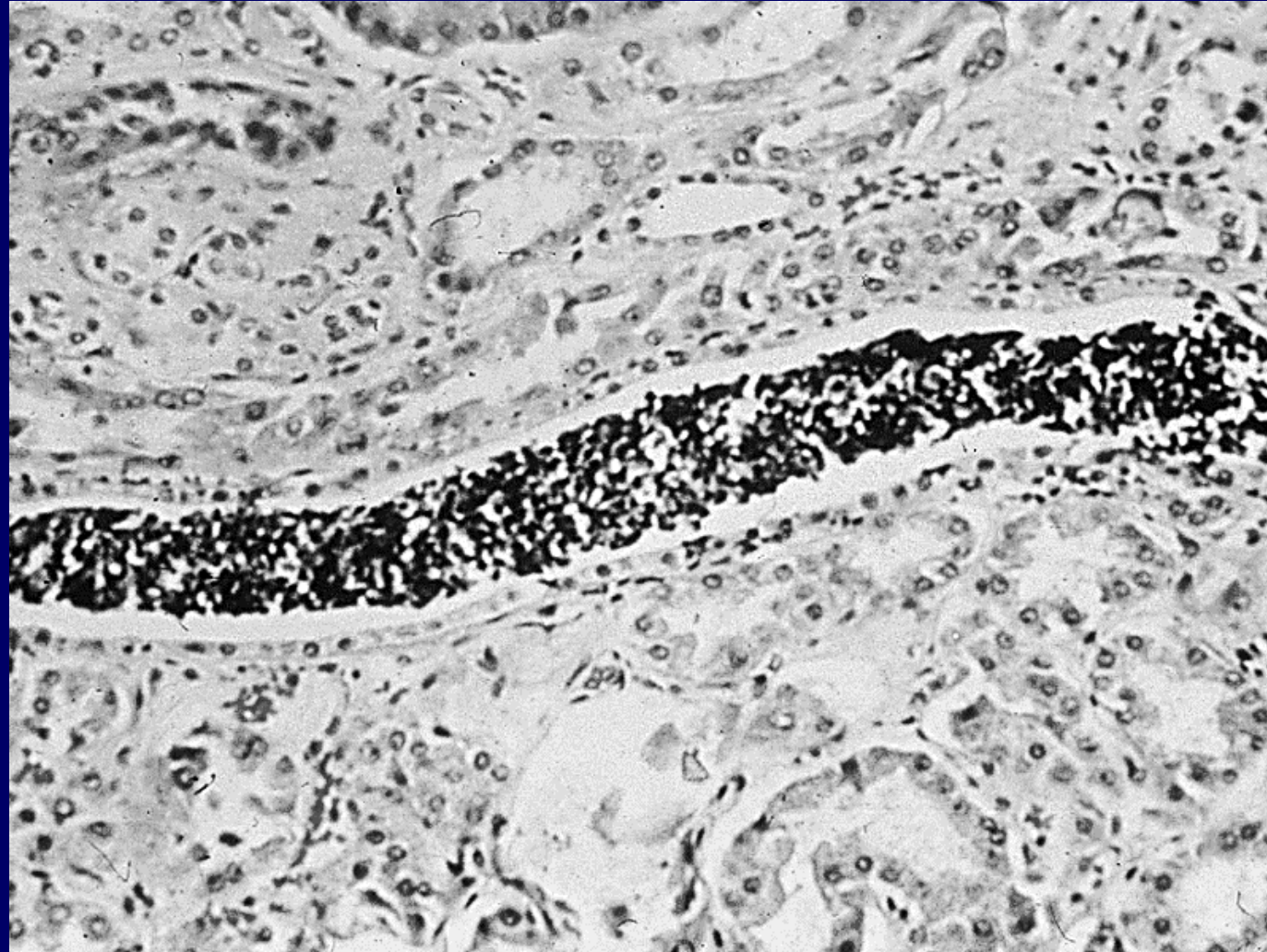
Microscopic Examination

RBCs Cast - Histology



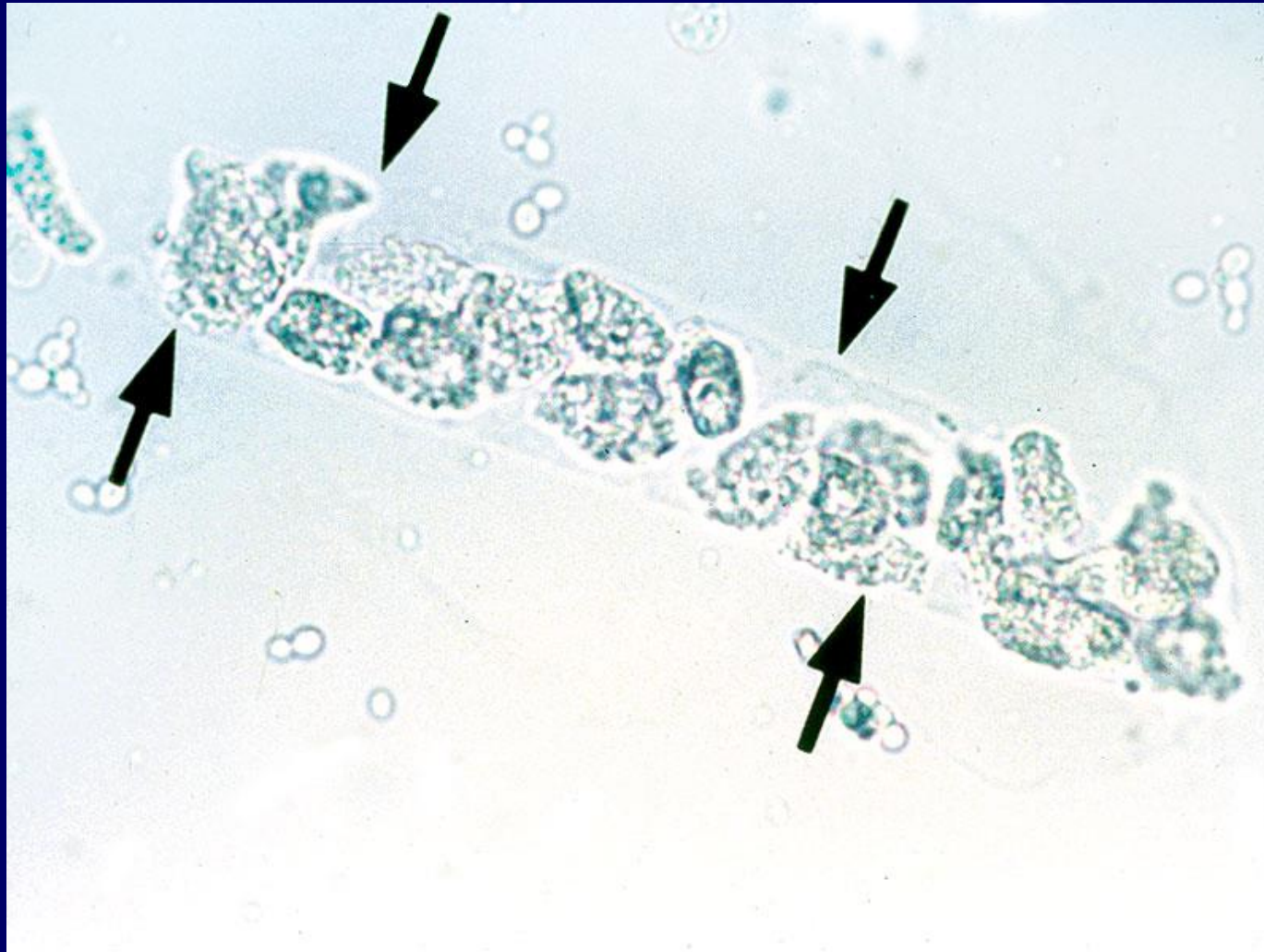Microscopic Examination

RBCs Cast - Histology



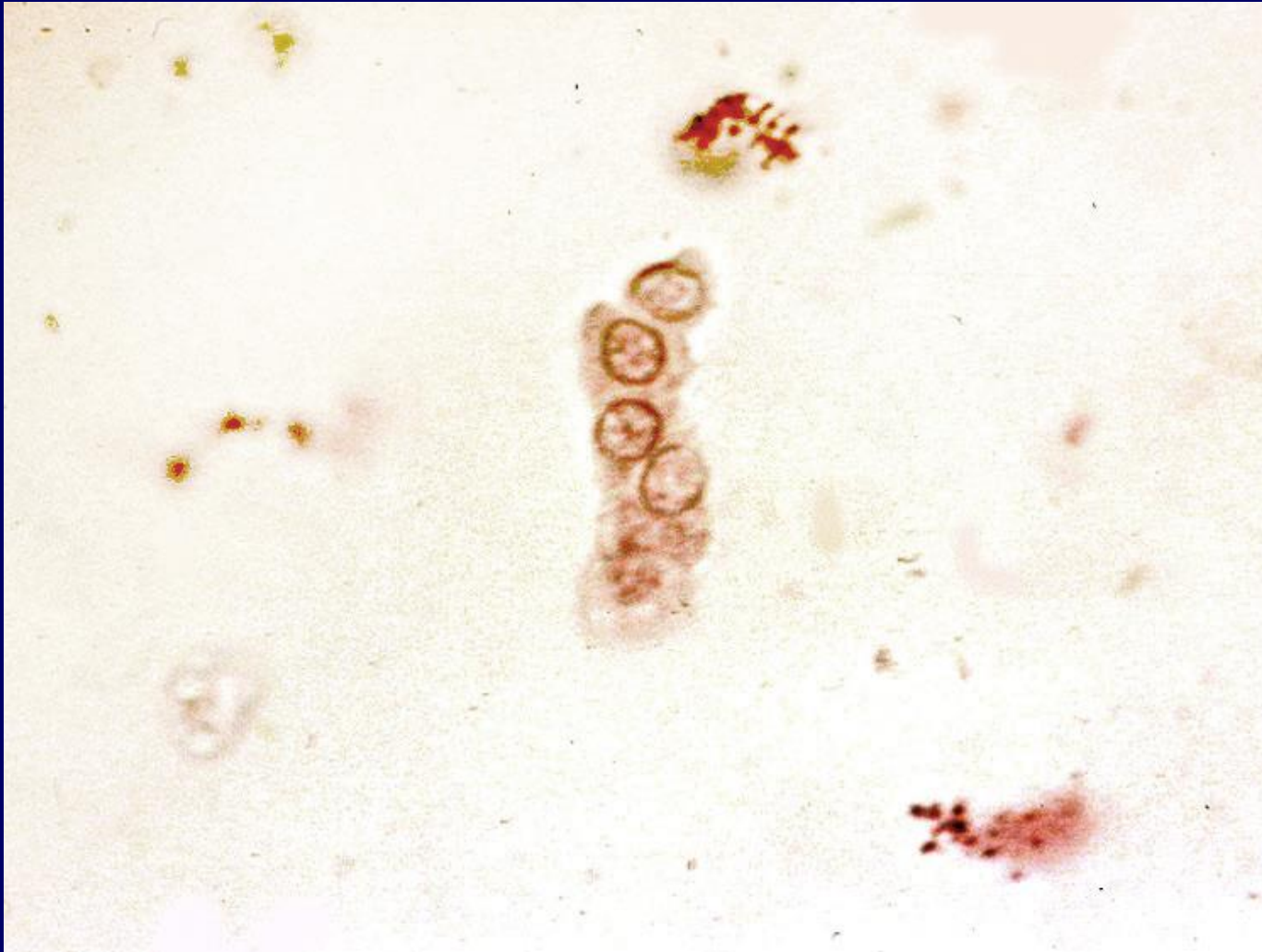Microscopic Examination

WBCs Cast - Histology



Microscopic Examination

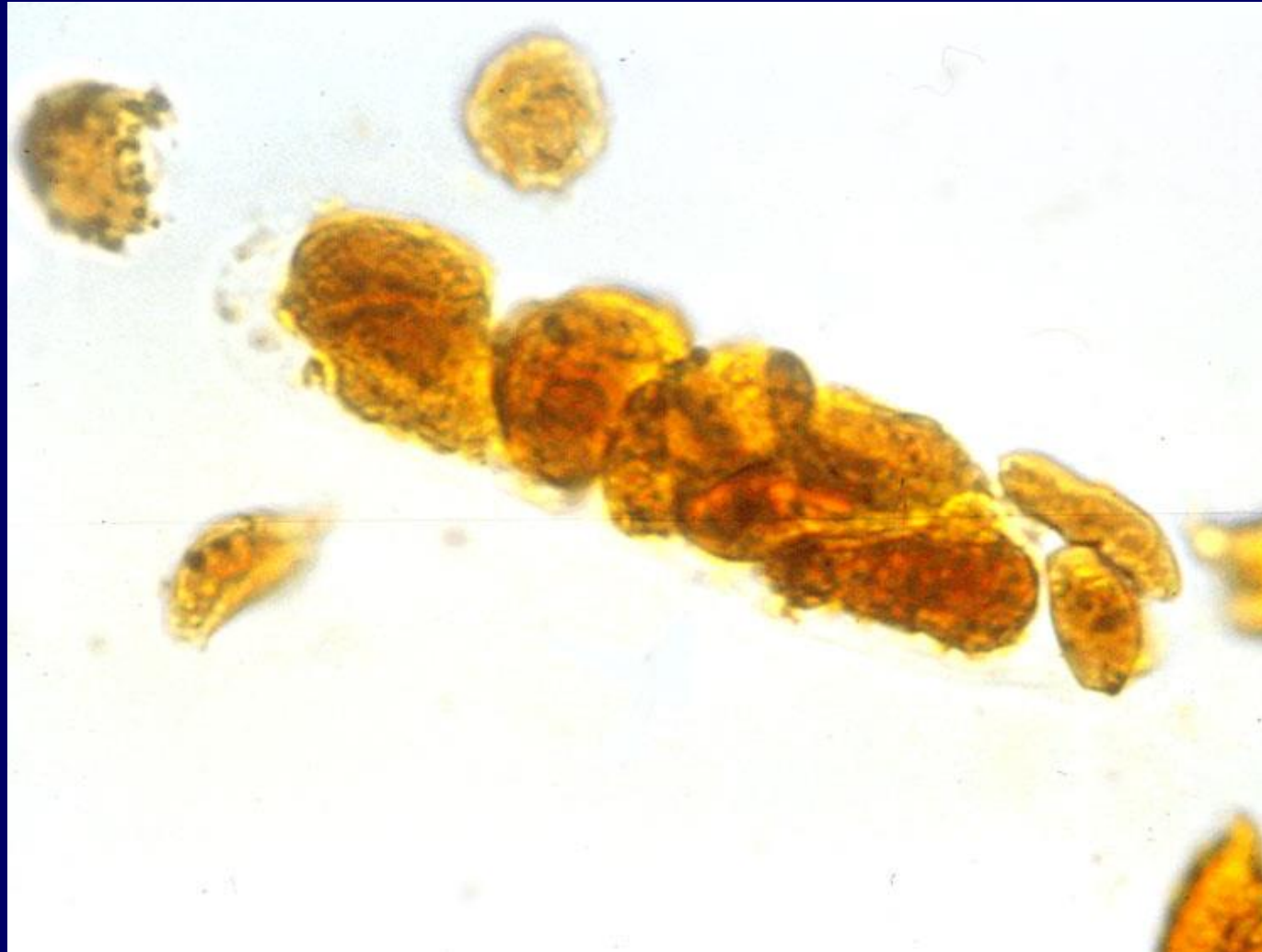
Tubular Epithelial Cast - Histology



صدمه و یا نکروز بافت اپی تلیال تیوبولهای کلیوی
گلوبرونفریت حاد و مزمن

Microscopic Examination

Tubular Epithelial Cast - Histology



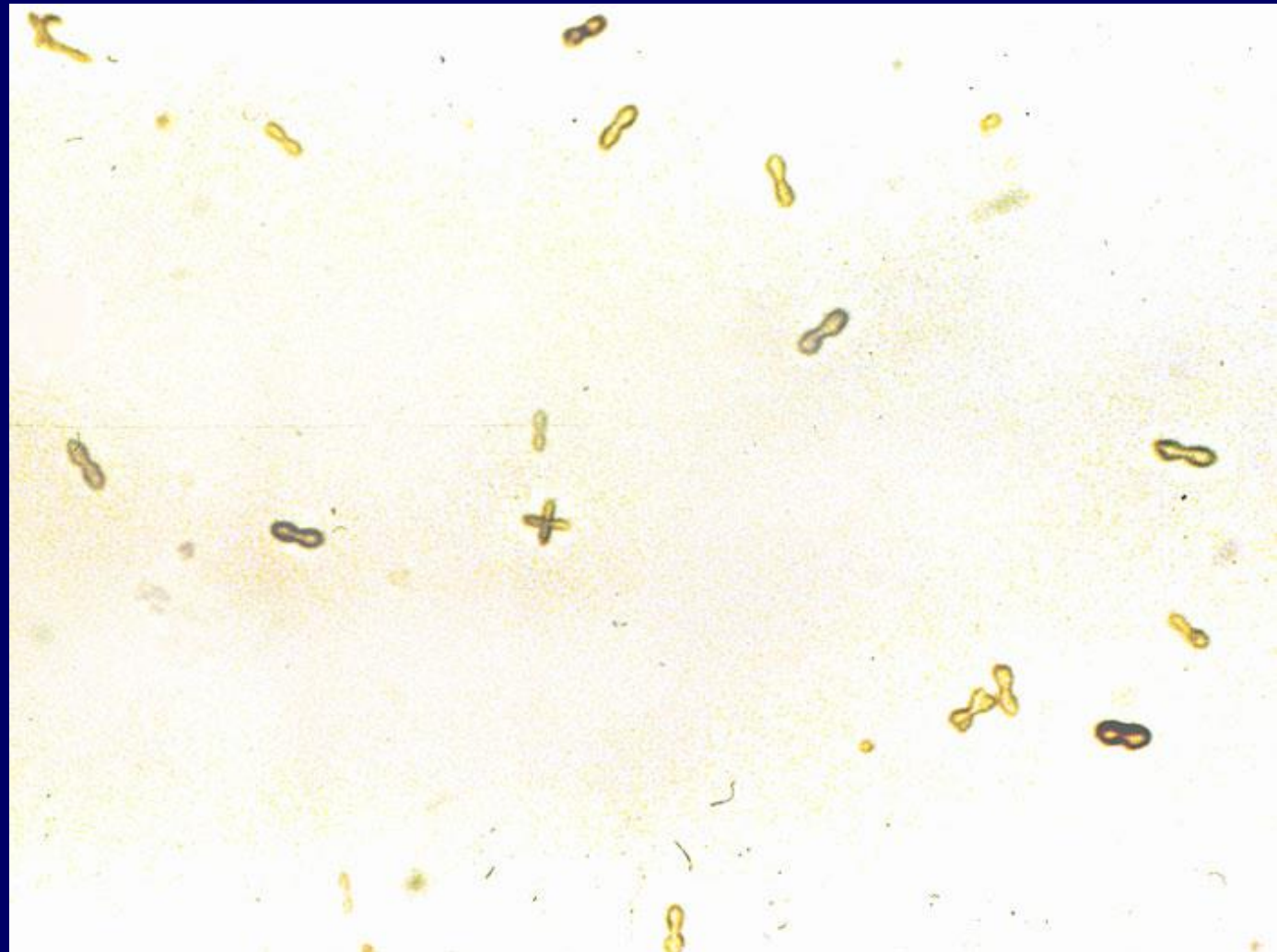
Microscopic Examination

Crystals

کم آبی بدن
تغییر در pH ادرار
عفونت دستگاه ادراری
Ca/C/N/OX

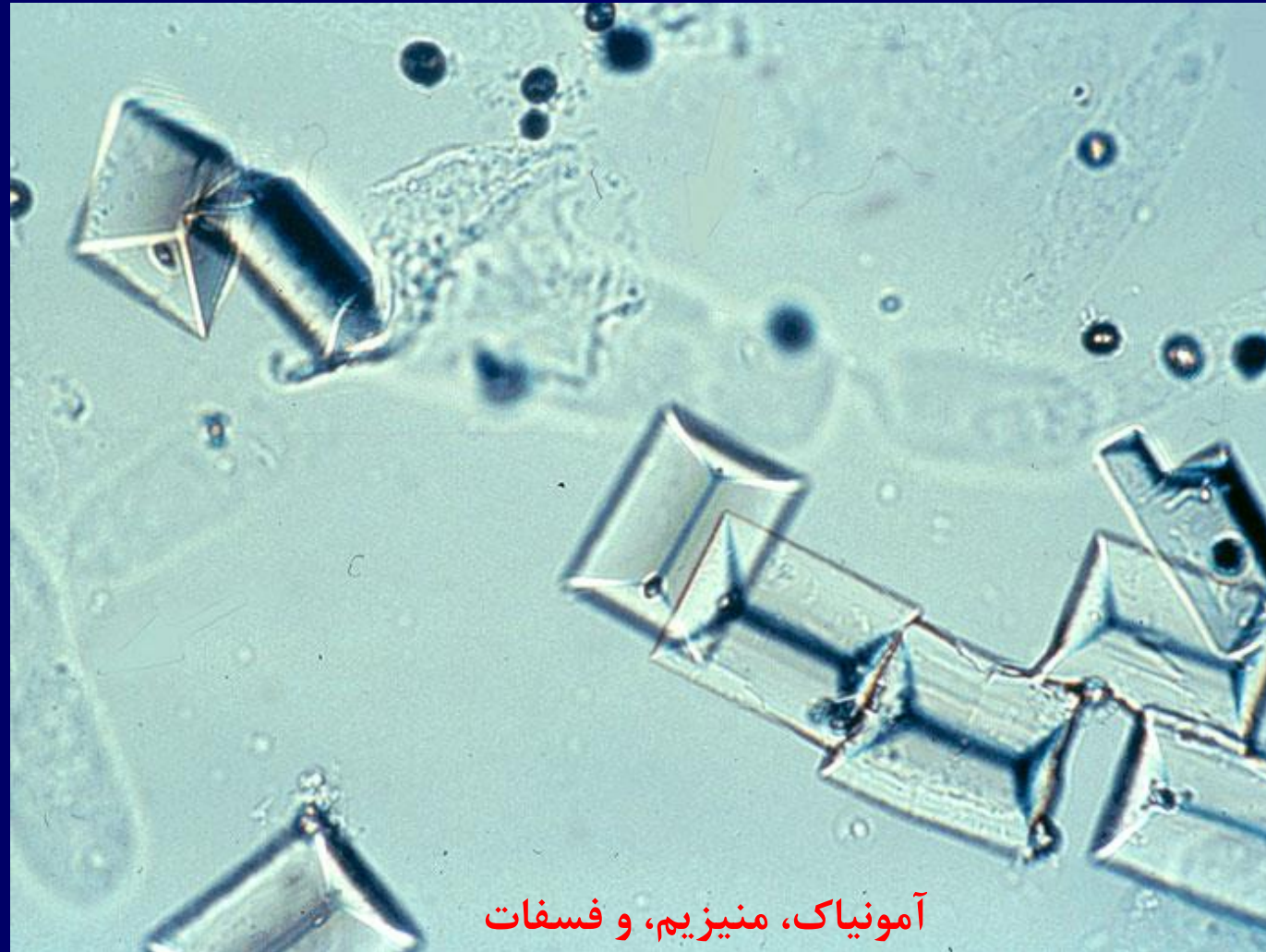Microscopic Examination

Calcium Oxalate Crystals



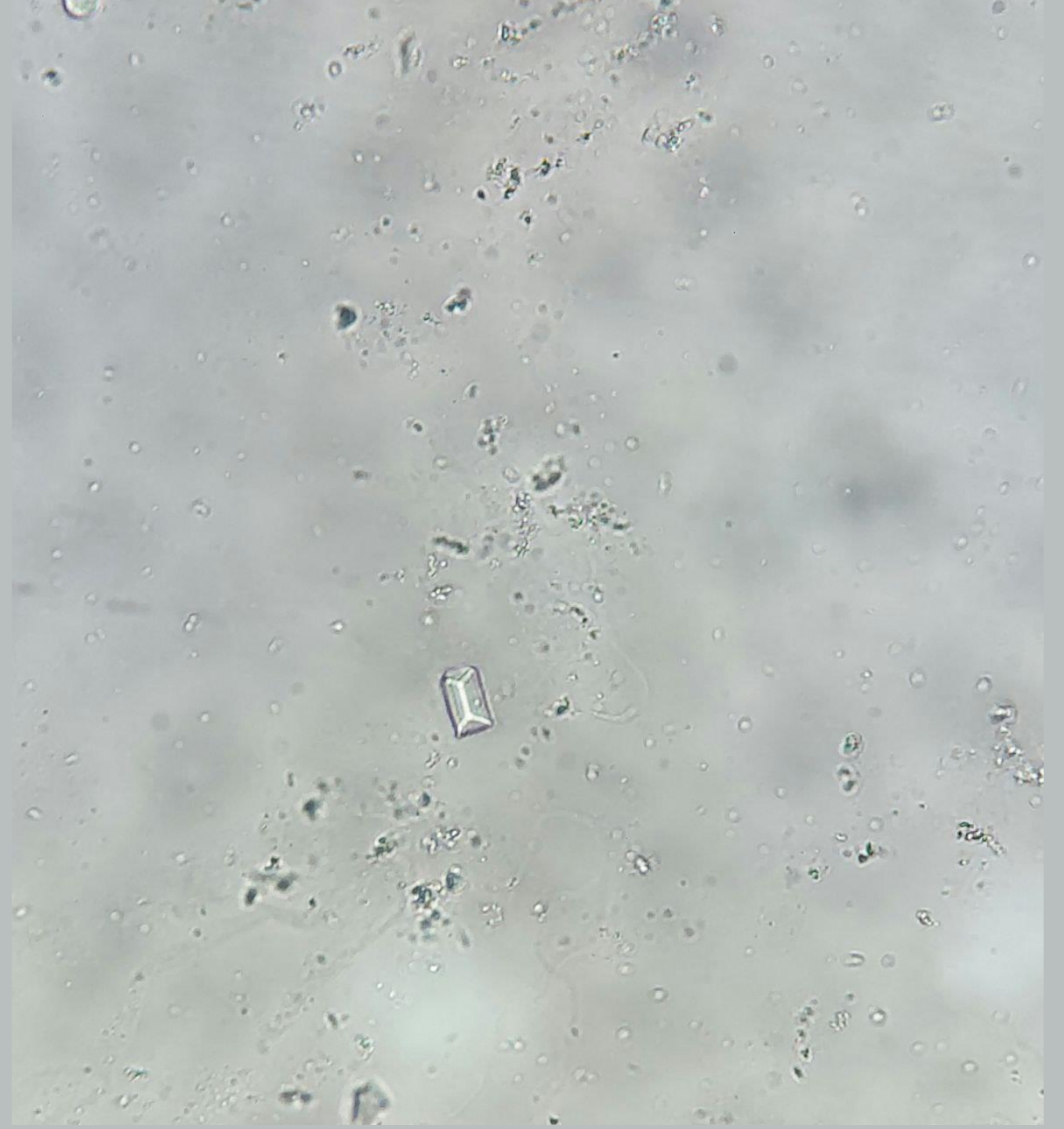
Microscopic Examination

Triple Phosphate Crystals



آمونیاک، منیزیم، و فسفات

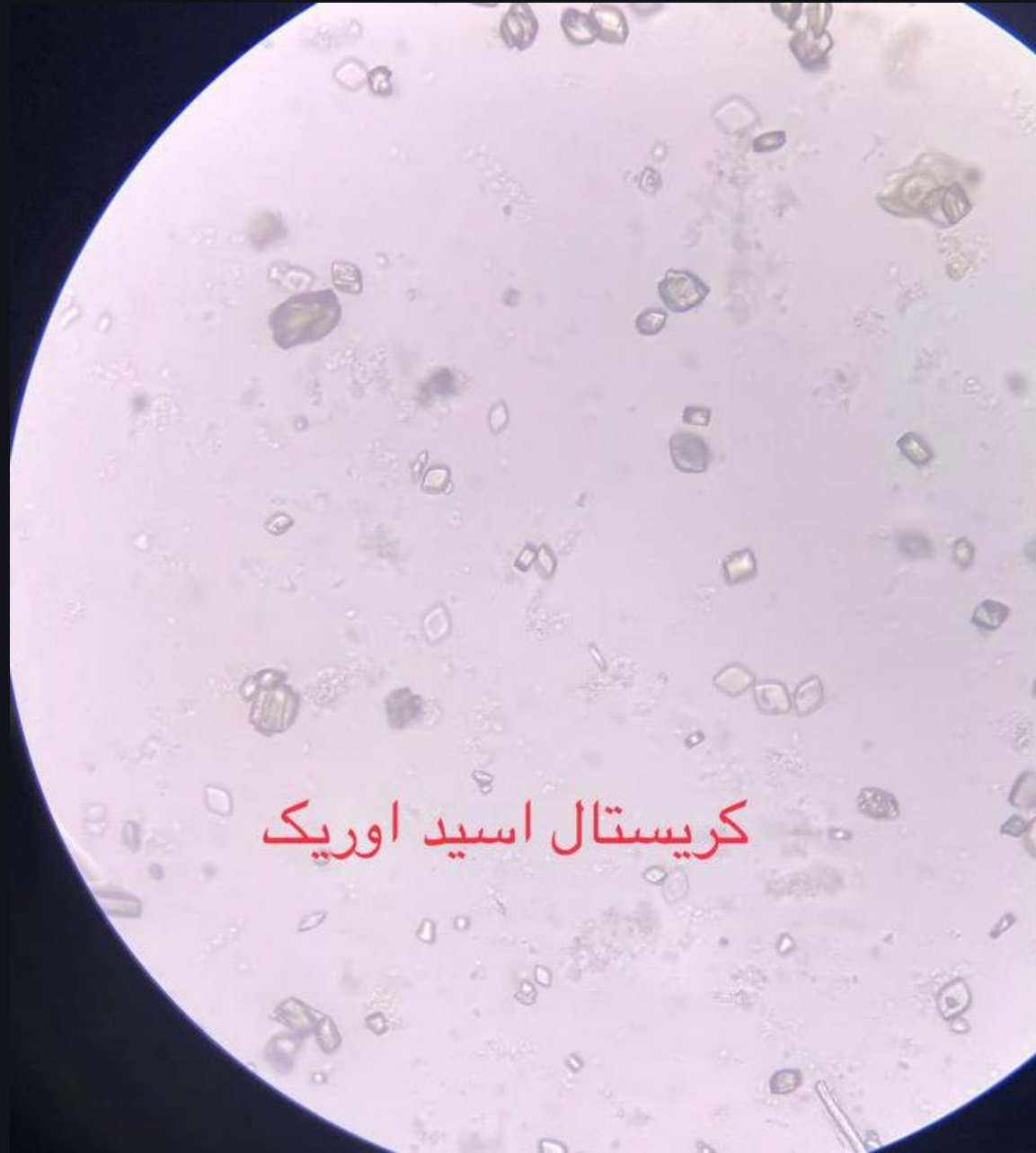
Triple Phosphate Crystals



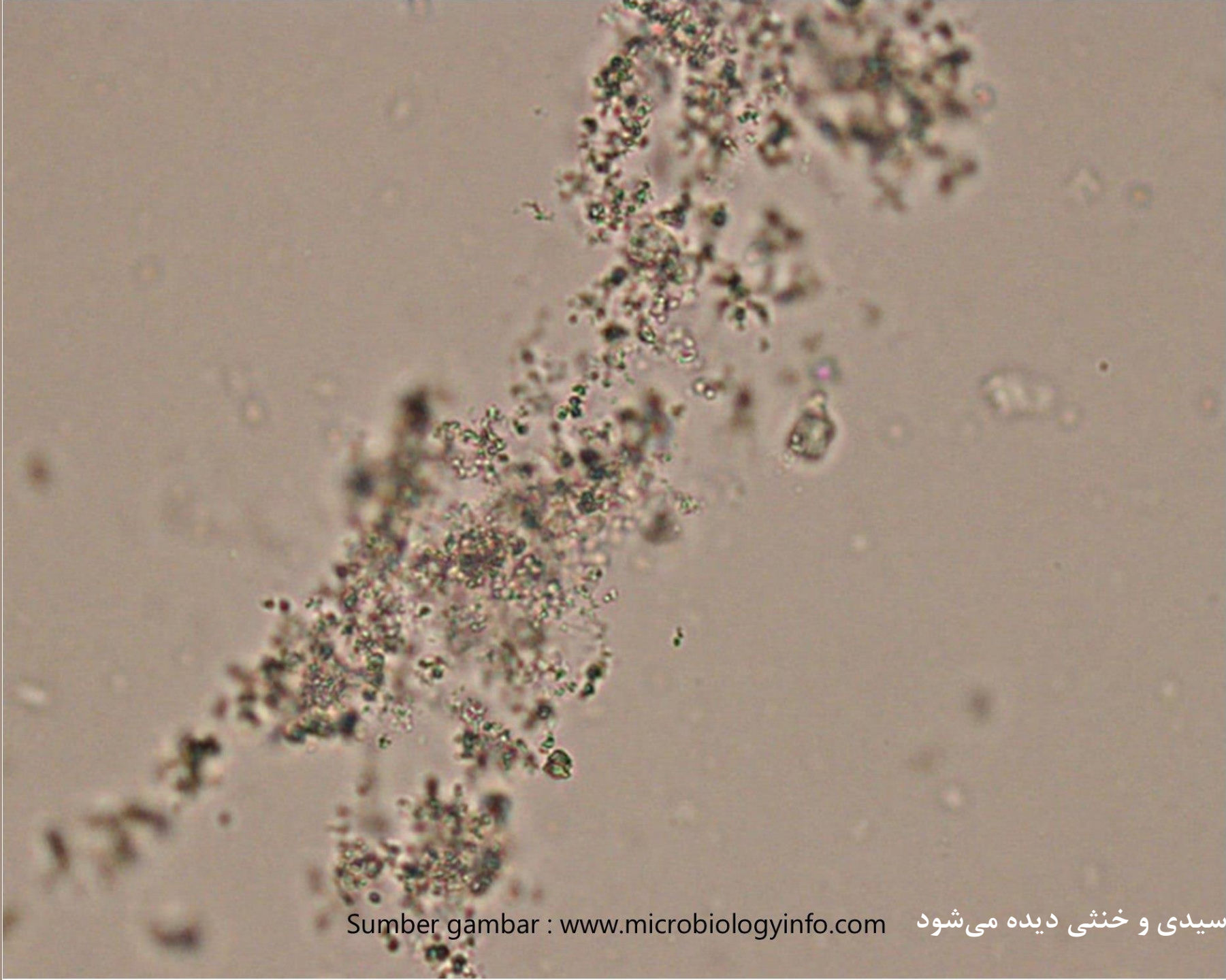
Microscopic Examination

Uric acid Crystals

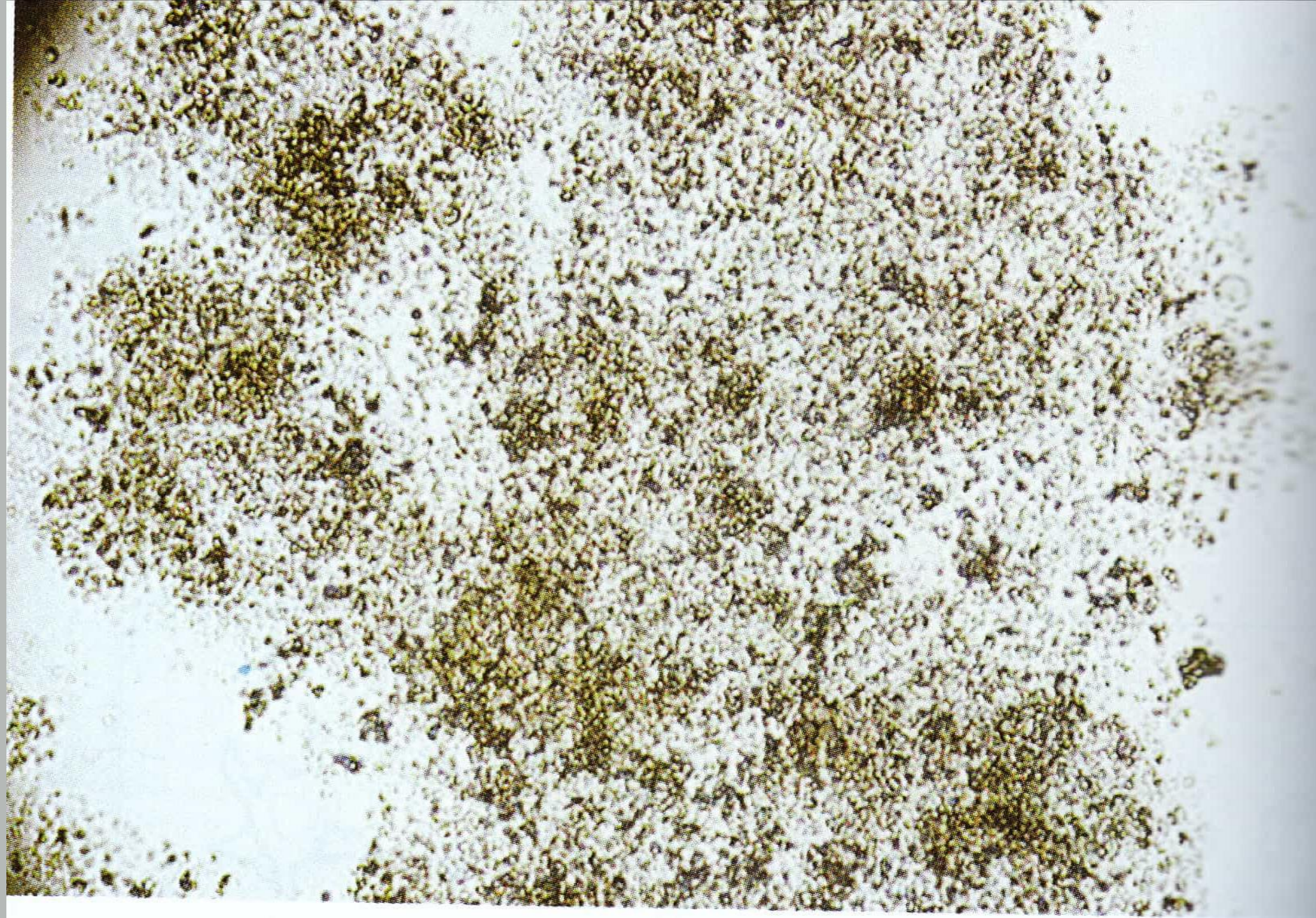




کریستال اسید اوریک



اورات آمورف در ادرار اسیدی و خنثی دیده می شود
Sumber gambar : www.microbiologyinfo.com



SI

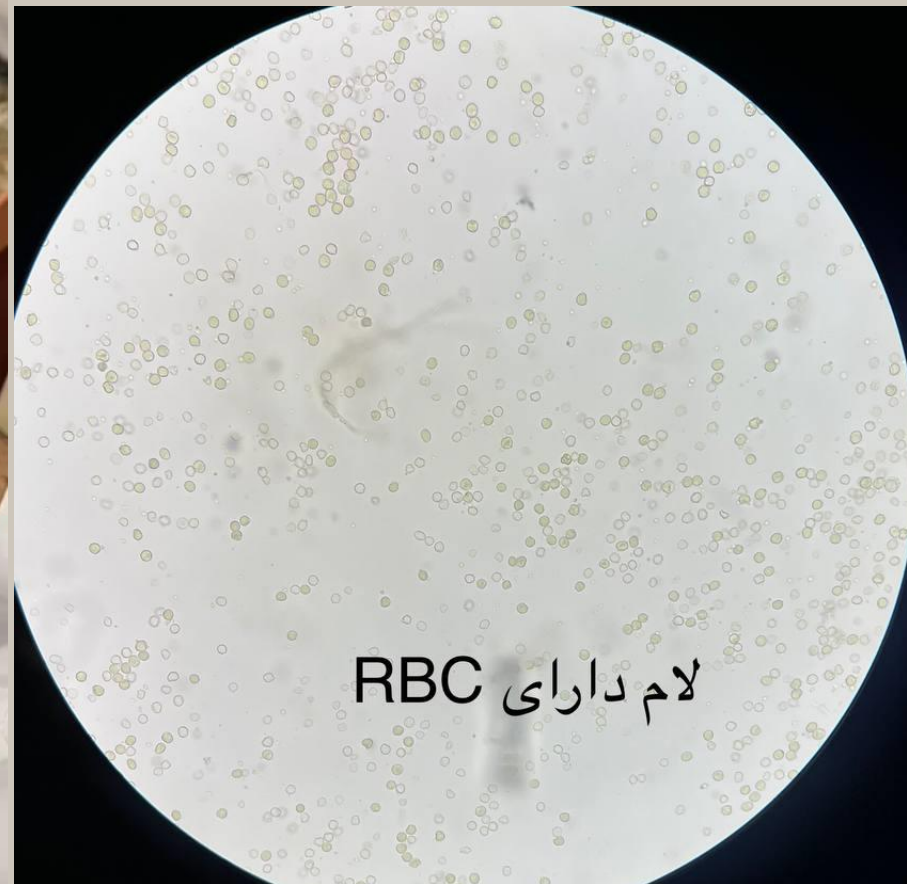
Amorphous Phosphate

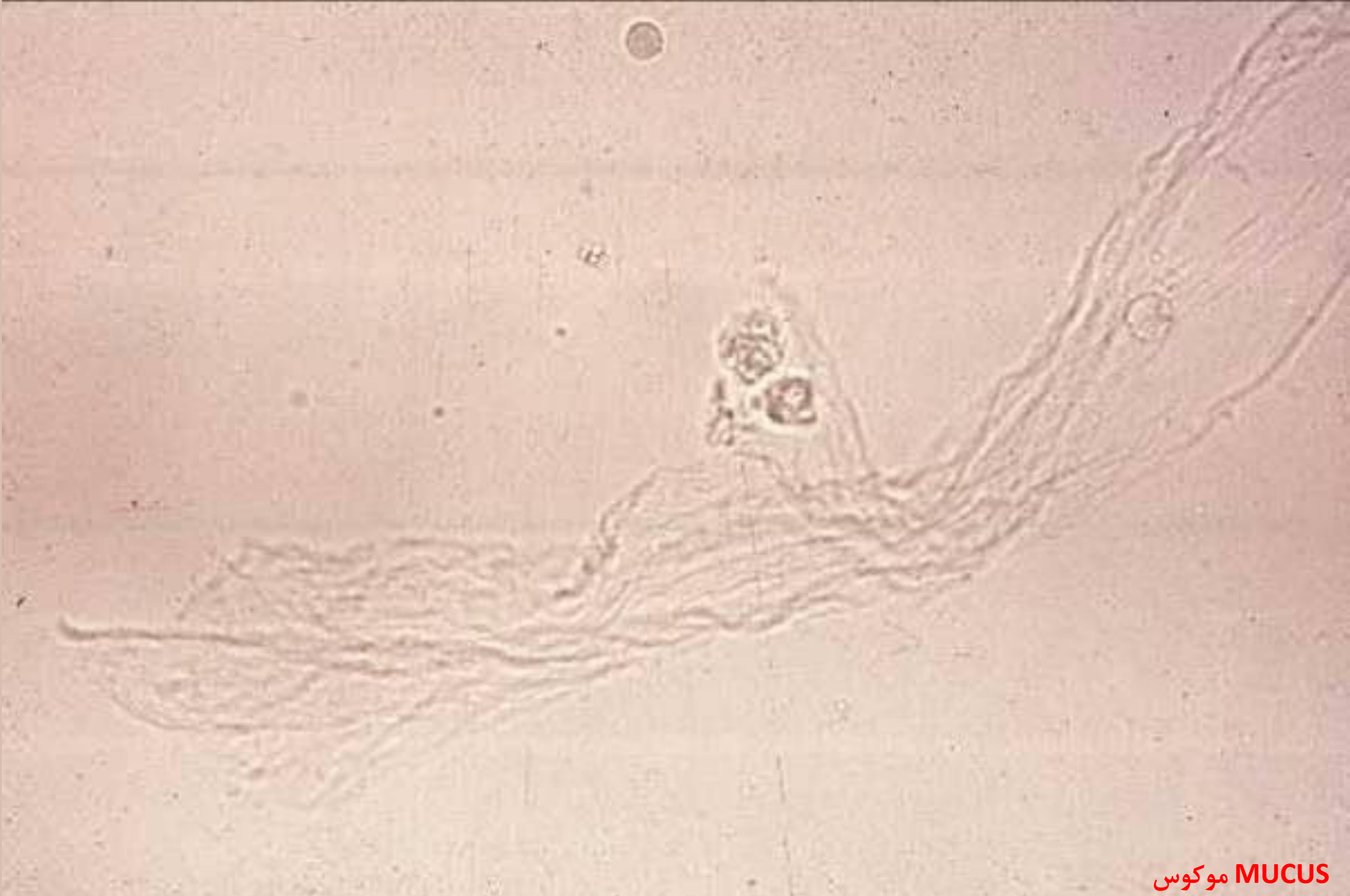


Scholar Idea

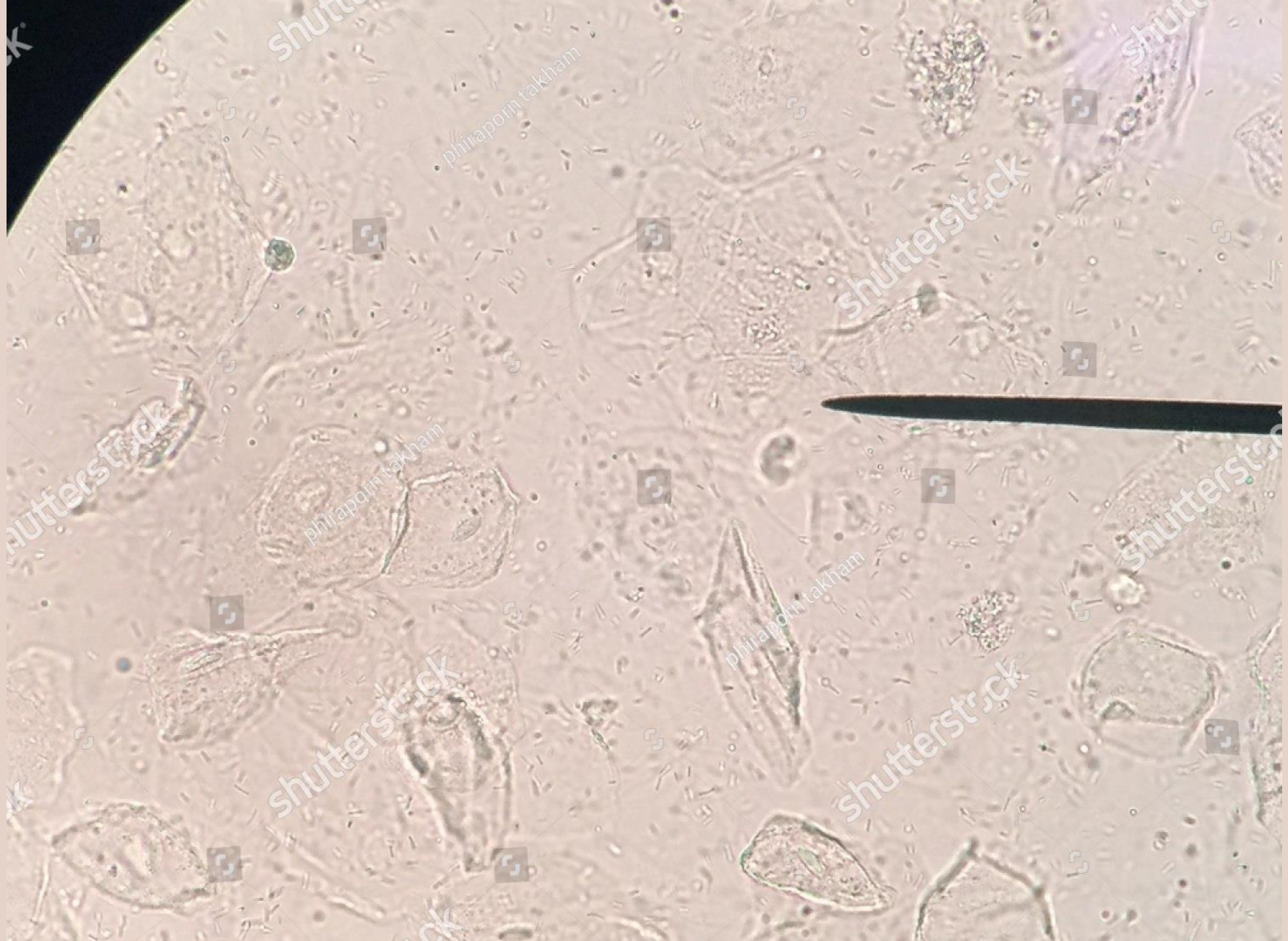
X40

فسفات آمورف در ادرار قلیایی دیده می شود





MUCUS موكوس



CLINICAL URINOLOGY

CROFTAN, ALFRED CAREN~O, 1871-



SRI LANKA ONLY • FOR SALE IN BANGLADESH, BHUTAN, INDIA, MALDIVES, NEPAL, PAKISTAN AND SRILANKA ONLY



FIFTH EDITION

Tietz Textbook of CLINICAL CHEMISTRY and MOLECULAR DIAGNOSTICS

Carl A. Burtis
Edward R. Ashwood
David E. Bruns

Restricted South Asia Edition

This edition is licensed for sale in Bangladesh, Bhutan, India, Maldives, Nepal, Pakistan and Sri Lanka only.
This edition is not authorized for export outside these territories.
Circulation of this edition outside these territories is unauthorized and illegal.

Expert **CONSULT**

Activate at expertconsult.com

Searchable Full
Text Online

Henry's

Clinical Diagnosis and Management by Laboratory Methods

22nd Edition



McPHERSON • PINCUS

ELSEVIER
SAUNDERS

The End